

# An unusual association between oral sarcoma and bulbar palsy

Tayseer M. Zein, MB, BS, Eivind J. Carlsen, MD, MRCP, Zein M. Mirghani, BSc, PhD.

---

## ABSTRACT

A 90 year old male presented with symptoms and signs of right lower cranial nerves palsy. A small mass was found on the right side at the back of his mouth. Light microscopy and histoimmunochemical studies of the biopsy of the mass showed an alveolar soft part sarcoma arising from the right myohyoid muscle. The unusual location and presentation of this rare tumor is discussed.

**Keywords:** Alveolar soft part sarcoma, bulbar palsy, lower cranial nerve palsy.

Neurosciences 2000; Vol. 5 (1): 72-73

---

The most common anatomical sites of lower cranial nerves lesions are the brain stem, the skull base and the neck. The lower cranial nerve nuclei in the brain stem can be affected by tumors, vascular lesions, motor neurone disease and syringobulbia. Chronic or malignant meningitis can infiltrate the lower cranial nerves along their path in the base of the skull. The peripheral trunks of these cranial nerves in the neck can be destroyed by tumors or trauma. We describe a rare case of alveolar soft part sarcoma emerging from the floor of the mouth presenting as isolated lower cranial nerve palsy.

**Case Report.** A 90 year old diabetic male presented with dysarthria, dysphonia and dysphagia for 3 weeks. He had no symptoms related to increase intracranial pressure or meningeal disease. He had no motor weakness or sensory symptoms. General examination including cardiovascular, chest and abdominal examinations were normal. He had no lymphadenopathy or other palpable masses. Positive neurological signs were: nasal speech dysarthria with dysphonia, absent gag reflex and tongue wasting on the right side with tongue deviation to the right. Blood tests and ECG were normal. Chest x-ray

showed bilateral basal opacities consistent with aspiration pneumonia. Brain and skull base MRI were normal. Neck, right mandible and abdominal CT-scans were normal. Direct laryngoscopy under anesthesia with a biopsy taken from the posterior pharynx were normal. EMG and nerve conduction studies were normal.

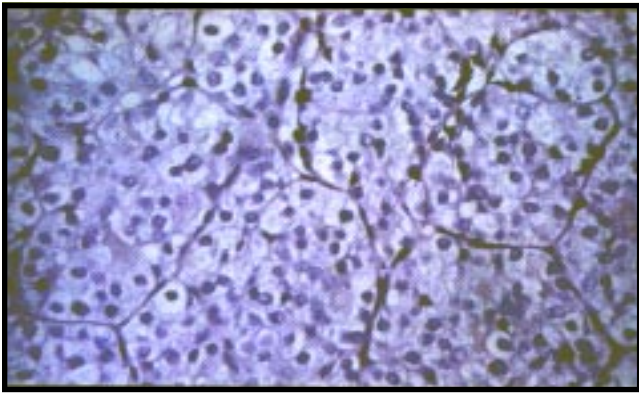
During the patient's stay in hospital, a lump the size of an almond located at the back of his mouth on the right side, was discovered. The mass was superficial, hard and fixed to the underlying structures. The histological examination of the biopsy taken from the right myohyoid muscle showed a neoplasm underlying, but not infiltrating, the oral mucosa. The shape of the cells were round or oval and had a moderate amount of vacuolated cytoplasm. This contained small, irregular PAS-positive bodies which were mostly resistant to diastase treatment. The nuclei were polymorphic, vesicular and contained one or two irregular nucleoli. The cells were growing in rounded colonies. These colonies being circumscribed by connective tissue; mostly reticulin (Figure 1). Cytokeratin, S-100 protein and desmin tests were negative whereas actin and vimentin tests were positive. Mitoses were few,

---

From the Department of Medicine, (Zein), Department of Pathology, (Carlsen), Armed Forces Hospital, Southern Region Khamis Mushayt, Department of Clinical Biochemistry, (Mirghani), College of Medicine, Abha, Kingdom of Saudi Arabia.

Published simultaneously with special permission from Saudi Medical Journal.

Address correspondence and reprint request to: Dr. Tayseer Zein, Department of Medicine, Armed Forces Hospital, Southern Region, PO Box 101, Khamis Mushayt, Kingdom of Saudi Arabia. Tel. (07) 251 1550 Fax. (07) 2511550



**Figure 1** - A high power photomicrograph showing the nesting arrangement of large tumor cells with prominent nucleoli, frequent mitotic figures and abundant granular cytoplasm (PAS Stain, original magnification x 200).

but apical. In the sparse stroma a few lymphocytes were found. Vascular invasion was not seen. The morphological picture corresponded to an alveolar soft-part sarcoma.

The patient died 3 weeks later. Post mortem examination was not carried out.

**Discussion.** The most common tumors presenting as isolated lower cranial nerve palsy are nasopharyngeal carcinoma<sup>1</sup> and glomus jugular tumor.<sup>2</sup> Germinoma of the medulla oblongata is a rare tumor which can present as lower cranial nerve palsy.<sup>3</sup> Tumor metastases to the brain stem can also present as isolated bulbar palsy.<sup>4</sup>

Alveolar soft-part sarcoma is rare, accounting for less than 1% of malignant soft tissue tumors, which are themselves unusual.<sup>5</sup> Histologically alveolar soft part sarcoma can mimic alveolar rhabdomyosarcoma, paraganglioma, metastatic renal cell carcinoma and malignant melanoma.<sup>6</sup> Therefore, demonstration of diastase resistant intracytoplasmic needle like structure by PAS stain and membrane bound crystals by electron microscopy is of great diagnostic value in alveolar soft part sarcoma.<sup>7,8</sup> The histogenesis of this unusual neoplasm has not yet been definitely established. Possibilities include malignant counterpart of granular cell tumor, non chromaffin paraganglioma or related to renin-producing cells of blood vessels walls.<sup>9</sup> However, the bulk of evidence favors a myogenous derivation.<sup>10</sup> This includes age, location and histologic architectural similarities between alveolar soft part sarcoma and alveolar rhabdomyosarcoma. Also in support of this opinion is the presence of ATPase activity in the intracytoplasmic crystalline inclusions.<sup>11</sup> Alveolar soft-part sarcoma usually presents at an early age and is more common seen in females. Most frequent sites are the lower extremities.<sup>12</sup> Reports of rare cases describe the presence of the tumor in the oral cavity without involving the tongue.<sup>13</sup> In contrast our patient is an

elderly male who had the tumor confined to the oral cavity only.

The most likely explanation of the unusual presentation of the tumor in this case is that the expansion of the tumor in the space between the right mandibular ramus and the cervical spine, resulted in the compression of the lower cranial trunks IX to XII lying within the carotid sheath in this area.

It was reported that alveolar soft tissue sarcoma may have characteristic MRI findings which may lead to early diagnosis of the tumor.<sup>14,15</sup> These MRI findings, which include high signals intensity on T<sub>2</sub> and T<sub>1</sub> WI, were not seen in our case.

## References

1. Tong Y, Wang JM, Huang CH. Syncope in nasopharyngeal carcinoma: report of 3 cases and review of the literature. *Chang Kang. I Hsuch* 1993; 16 (1): 59.
2. Megerian CA, McKanna MJ, Nadol JB. Non-paraganglioma jugular foramen lesions masquerading as glomus jugulae tumour. *Am J Otol* 1995; 16 (10): 9.
3. Surgiyama K, Kozumi T, Goishi J, Sogabe T, Arita K, Maeda H et al. Germinoma of the medulla oblongata, case report. *Naerol Med Chir Tokyo* 1994; 34 (5): 291-294.
4. Hammond PR, Mackenzie IR. Xanthoma dissemination with massive intracranial involvement. *Clin Neuropath* 1995; 14 (6): 314-321.
5. Hanna NN, O' Donnell K, Wolfe GR. Alveolar soft part sarcoma metastatic to the breast. *J Surg Oncol* 1996; 61 (2): 159-162.
6. Balfour RS. The alveolar soft-part sarcoma, Review of the literature and report of a case. *J Oral Surg* 1974; (3): 214-200.
7. Penny JR, Bilbao JM. Metastatic alveolar soft part sarcoma presenting as a dural-based cerebral mass. *Neurosurgery* 1994; 34 (1): 168-170.
8. Husain M, Nguyen GK. Alveolar soft-part sarcoma. Report of a case diagnosed by needle aspiration cytology and electron microscopy. *Acta-Cytol* 1995; 39 (5): 951-954.
9. Lieberman PH, Brennan MF, Kimmel M, Erlandson RA, Garin-Chesa P, Flehinger BY. Alveolar soft-part sarcoma. A clinico-pathologic study of half a century. *Cancer* 1989; 63: 1-13.
10. Sciort R, Dal-Cin P, De Vos R, Van Damme B, Denever I, Va-den Berghe H et al. Alveolar soft part sarcoma: evidence for its myogenic origin and for the involvement of 17q25. *Histopathology* 1993; 23 (5): 439-444.
11. Fosschini MP, Eusebi V. Alveolar soft part sarcoma. A new type of rhabdomyosarcoma? *Semin Diagn Pathol* 1994; 11: 58-68.
12. Nakashima Y, Kotoura Y, Kasakura K, Yamanuro T, Amitani R, Ohdera K et al. Alveolar soft-part sarcoma. A report of ten cases. *Clin-Orthop* 1993; (294): 259-266.
13. Marker P, Jensen ML, Siemssen SJ. Alveolar soft-part sarcoma, report of a case and review of the literature. *J Oral Maxillofac Surg* 53 1995; (10): 1203-1208.
14. Iwamoto Y, Morimoto N, Chuman H, Shimohara N, Sugioka Y et al. The role of MR imaging in the diagnosis of alveolar soft-part sarcoma: a report of 10 cases. *Skeletal-Radiol* 1995; 24 (4): 267-270.
15. Temple HT, Scully SP, O' Keepe RJ, Rosenthal DI, Mankin HJ. Clinical presentation of alveolar soft-part sarcoma. *Clin-Orthop* 1994; (300): 213-218.