

Arabic melodic and rhythmic therapy

A method of severe aphasia therapy

Fawzi Jalled, Hichem Skik, Amel Mrabet.

ABSTRACT

The necessity of a therapy allowing aphasics to be rehabilitated quickly in social life urged us to adapt a therapeutic strategy developed in the USA and implemented in France under “*therapie melodique et rythmee*”. This model of language therapy has been destined to aphasics with good auditory comprehension and emotional stability despite severe language impairment. A careful evaluation of the patient is necessary to select the candidates for exposure to this therapy. Our evaluation is based on an examination battery (made of repetition, naming, auditory comprehension), items inspired by the Boston Diagnostic Aphasia Examination and adapted to Tunisian context. This method relies on the prosodic features of Tunisian Arabic (melody patterns, rhythm, pitch, stress) and proceeds from non verbal exercises. The latter are realised by a corpus of texts of various length and structure. Applying Arabic melodic and rhythmic therapy allowed patients to recover the capacity to communicate to different degrees with others.

Keywords: Severe aphasia, stroke, speech therapy, prosody, Arabic language.

Neurosciences 2000; Vol. 5 (2): 91-93

Stroke and cranial traumatism constitute frequent neurological diseases which affect patients at any age, particularly after 45 years. Severe speech difficulties such as mutism or stereotypes, frequent in these diseases, require diagnosis and early speech therapy, which ensure to the aphasic patient a better recovery and a rapid social reintegration. Arabic melodic and rhythmic therapy (AMRT) is an efficient method of speech therapy for patients suffering from severe and prolonged reduction of oral language. This therapeutic method is an Arabic version of melodic and rhythmic therapy (MRT) developed by Van Eeckhout et al¹ following another French version adapted from an American method known as melodic intonation therapy (MIT) described in many publications by Albert et al², Sparks et al³ and Robert et al⁴. It enables patients to overcome verbal expression problems via rhythm, melody and accentuation that constitute an auditory stimulus and a means of easing and re-acquisition of verbal

autonomy. Patients included are those likely to profit from AMRT and should satisfy the following criteria: (1) localisation of the cerebral impairment in the anterior zones of the left hemisphere; (2) important reduction of oral expression with significant articulatory disorders; (3) preservation of oral comprehension; (4) absence of anosognosia and/or auditory reception disorders; (5) a good emotional stability: absence of spasmodic laughter and tears in particular hypersensitivity in old patients. The inclusion of patients and the evaluation of the severity of aphasia and its evolution following the onset of re-education, are based on administering of three tests of Boston Diagnostic Aphasia Examination (BDAE)⁵ such as repetition, naming and oral comprehension. We have elaborated and adapted to the Tunisian context these three tests in order to assess oral comprehension of the patients of Neurological Department at Charles Nicolle Hospital.

From the Neurological Department (Jalled, Mrabet), EPS Charles Nicolle, Tunis, Tunisia, La Monouba University of Tunisia (Skik), Tunis, Tunisia.

Received 13th September 1999. Accepted for publication in final form 9th November 1999.

Address correspondence and reprint request to: Professor Amel Mrabet, Neurological Department, EPS Charles Nicolle, 1006 Tunis, Tunisia. Tel & Fax: 00 216 1 562 834. E-mail: amel.mrabet@rns.tn

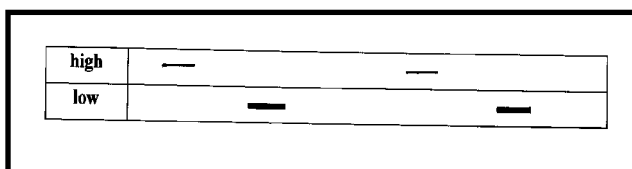


Figure 1

Findings. Corpus. Applying this method to Arabic required the construction of a corpus of spoken Arabic adapted to the Tunisian context. The corpus is based on the exploitation of prosodic features of spoken Arabic, such as melody, rhythm and accentuation, to facilitate auditory reception and oral emission of phonemic and syntactic components. Spoken Arabic prosody organises physical parameters of height, duration and intensity according to schemas that are specific to it and which differ from those of French. Indeed, vocalic duration is used in Arabic to distinguish phonemes, which is not the case in French. Thus, the lexeme [ʔ mal] (he did) is different from [ʔ ma:l] (actions), and this difference in meaning is obtained only by vowel length: short [a] in [ʔ mal], long [a:] in [ʔ ma:l]. In French, however, the lexeme “formidable” pronounced with a long [o:] is not a different word from “formidable” pronounced with a normal [o]: it is simply stylistically more expressive. This vowel length in Arabic restricts the possibilities of using it to highlight one feature or another, as it is the case with TMR in French.

Accent. In Arabic, the accent falls on the ultimate or penultimate syllable while in French it always falls on the ultimate syllable.

Melodic curve. Well studied in French, and understudied in Arabic, the melodic curve is certainly different in the two languages. We will propose to Tunisian patients utterance in spoken Arabic with intonation approximating natural intonation.

The items of this corpus are made up of utterance of various length and syntactic structure. They include a simple vocabulary dealing with themes belonging to the Tunisian speaker’s everyday life, and causing no special comprehension problem even to non-educated patients (daily actions, greeting idioms, etc....). A corpus adapted to patients with a higher educational level in Arabic has been prepared

and includes different texts in standard Arabic.

The use of AMRT: It is based on a chronological proceeding of a series of non-verbal and then verbal exercises. During the first stage, the speech therapist makes his patient listen to rhythms caused by tapping the table at regular and then varied intervals. He asks his patient to repeat these rhythmic sequences after a latency period which increases according to the success of the item: we end up with “a rhythmic and melodic conversation”, in the form of stimulation/response, between the therapist and the patient. This non-verbal “conversation” consists in humming some rhythmic sequences, alternating two notes: one is high and the other is low, the height interval separating these two notes being in principle perfect fourth (Do-Fa).⁶ At the end of these exercises, the patient, who is educated of course, must be able to decode himself a melodic schema by humming and chanting it as in Figure 1. Once the patient is able to master non-verbal exercises, the therapist moves to the second stage by introducing a verbal context based on the items of the above-mentioned corpus. Verbal exercises make a progress similar to that of non-verbal exercises.

Indeed, after the listening stage, the patient is invited to repeat full sentences, first with the therapist’s full support, and then with a lesser support as the patient must finish, alone, the repetition of the item, assisted at the beginning by the therapist. Then, the patient must repeat alone longer and longer sentences after a certain latency period as in Figures 2a, b). During the repetition of the items, the utterance of all the elements of the sentence is demanded without insisting too much on articulatory quality.⁷ Eventually, one begins the game of “questions/answers” which encourages the patient’s spontaneous speech according to his own melodic schemas, allowing him to express himself in different ways until he re-acquires a natural prosody. Our experiment was carried out with six patients (3 men and 3 women), right-handed aged from 42 to 67 years, and sent to us for a suspension or a severe reduction of oral language caused by an ischemic stroke. The early aphasiologic checkup included repetition, naming and oral comprehension tests inspired by the BDAE and adapted to the Arabic language. It revealed an important reduction of oral language with variable alterations.

The obtained results vary from one patient to

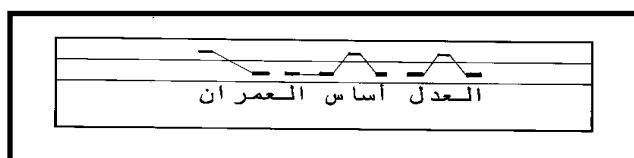


Figure 2a

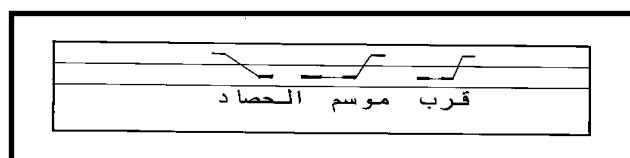


Figure 2b

another, according to the duration of the therapy, age, educational level and mainly according to determination and motivation. Our intervention allowed these patients to recover the capacity to communicate with others, using short, intelligible and informative sentences, as well as to repeat long sentences in a correct way, form sentences with two or three lexemes, and describe some pictorial scenes using sentences variable in length. Eventually, it allowed them to move to the stage of questions/answers.

Discussion. The classical techniques of aphasic therapy based on the correction of articulation and the repetition of lexemes and sentences, are inefficient and cannot solve the problem of mutism and stereotypy caused by severe and prolonged aphasias.⁸ Considering the stimulating results achieved by the implementation of TMR for 25 years in the USA and 20 years in France, we have decided to adapt this therapeutic strategy to the Arabic language. In order to understand the neurophysiological mechanisms intervening in language recovery through TMR a team of French researchers⁹ studied the use of a recent technique of functional scanning, the position emission tomography (PET). It was the case of seven aphasic right-handed patients, with no spontaneous language for months, even for years, despite the use of the usual therapy techniques, who have recovered an informative language with TMR. The PET measures the cerebral metabolic activity, using the cerebral regional blood flow (CrBF) and identify the cerebral areas involved in the accomplishment of sensory-motor and cognitive tasks. The CrBF of these patients was measured with H₂O15 in four activation conditions: 1) rest 2) listening 3) simple repetition 4) repetition with TMR. The listening and simple repetition of lexemes brought about the activation of some structures of the right hemisphere; whereas the repetition of lexemes with TMR reactivated a network of zones related to language in the left hemisphere: Heschl gyrus, temporal pole, angular gyrus, Broca's areas and the adjacent prefrontal cortex. As a result, the PET revealed the reactivation by the TMR of left hemisphere zones troubled by cerebral impairment and certainly playing a crucial role in language recovery; it also allowed to bring out Broca's and Wernicke's areas hypoperfusion, generally safeguarded on IRM. The implementation of TMRA on our patients brought about the following remarks: some patients showed a tendency to speak with a natural prosody and a corresponding rhythm without resorting to the accentuation of the different elements of the proposed corpus. The corpus is made up of sentences illustrating pieces of information provided by the patient's close family circle and related to his former socio-cultural activities, four patients had

some difficulty in using the visual schema, which completes the other three facilitating elements: rhythm, melody and accentuation (Figure 2a or 2b). This schema allows the command of the melody and the rhythmic quality of the corpus, energizes articulation, de-conditions the patients to oral starting up and oral/facial gesticulation, and then favours auditory reception.

The achievements of the mental and visual representation of the melodic and rhythmic schema of the sentence vary from a patient to another. This variation is due essentially to the non-schooling of some patients who are not used to symbols and to all that is related to graphics, taking charge of some patients was irregular because of the far distance of their homes from the hospital. The global duration of the TMRA implementation varies from a patient to another. It depends closely on the reappearance of language which is itself dependent on the degree of the patient's impairment, age, socio-cultural level, as well as on his regular presence to therapy sessions and the consolidation of acquisitions by his family circle. The average duration lasts from about 3 to 4 months.

In conclusion, the major purpose of this therapeutic action goes beyond the reappearance of speech and the provoked repetition of some lexemes and/or a few sentences, and tends to the command and representation of a facilitating model which helps to recover and energize daily verbal communication with others. The TMRA forms a new therapy technique of severe aphasias that can be implemented in our country.

References

1. Van Eeckhout P, Allichon J. Reeducation par la melodie des sujets atteints d'aphasie. *Reeduc Orthophonique* 1978; 16: 23-32.
2. Albert M, Sparks R, Helm N. Melodic intonation therapy for aphasia. *Arch Neurol* 1973; 29: 130-131.
3. Sparks R, Helm N, Albert M. Aphasia rehabilitation resulting from melodic intonation therapy. *Cortex* 1974; 10, 4: 303-306.
4. Robert W, Sparks R, John W. Deck; In *Language intervention strategies in adult aphasia*. Roberta Chapey, Ed. D; Third edition; Williams and Wilkins; Baltimore, Maryland 1994; 21202: 368-379.
5. *Boston diagnostic aphasia examination*. De H Goodglass et E Kaplan; Echelle française, adaptee en 1981 par JM Mazaux et JM Orgogozo. Editions scientifiques et psychologiques, Issy-Les-Moulineaux, France 1982.
6. Van Eeckhout P, Honrado C, Bhatt P, Deblais JC. De la TMR et de sa pratique. *Reeduc Orthophonique* 1983; 21, 132: 305-316.
7. Van Eeckhout P, Bhatt P, Honrado C, Deblais JC. De la TMR et de sa pratique. *Reeduc Orthophonique* 1983, 21, 132: 305-316.
8. Van Eeckhout P, Bhatt P. Rythme, intonation, accentuation: la reeducation des aphasies non fluentes severes. *Reeduc Orthophonique* 1984; 22, 138: 311-325.
9. Van Eeckhout P, Backchine S, Chomel De Varagnes S, Francois C, Lehermitte F. La therapie melodique et rythmee. *Reeduc Orthophonique* 1995; 33, 184: 379-396.