# Sixth nerve palsy and sphenoidal sinusitis

***Ammar F. Mubaidin,*** *MRCP,* ***Mohammed A. Hairi****, FRCR.*

## ABSTRACT

Sphenoid sinusitis is an uncommon infection that accounts for approximately 3% of all cases of acute sinusitis. It is usually accompanied by pansinusitis; less commonly it occurs alone. We are presenting a case of a 30 year old young male patient who presented with three weeks history of headache, along with blurry vision and diplopia. Neurological examination showed evidence of bilateral sixth nerve palsy. Brain magnetic resonance imaging showed evidence of pansinusitis, including sphenoidal sinusitis. Cerebrospinal fluid studies showed no evidence of meningitis.

**Keywords:** Sinusitis, sphenoid, sixth nerve palsy.

**Neurosciences 2000; Vol. 5 (3): 174-176**

Sphenoid sinusitis, although it accounts for approximately 3% of all cases of acute sinusitis, it is associated with significant morbidity and mortality. Complications of sphenoid sinusitis include aseptic meningitis, osteomyelitis, subperiosteal abscess, visual loss, multiple cranial nerve palsies, and papilledema. Computerized tomography (CT) or magnetic resonance imaging (MRI) is necessary for diagnosis of sphenoidal sinusitis, because plain x-rays can miss the diagnosis in about one third of cases.

Case report. A 30 year old male patient, with a long standing history of frequent attacks of sinusitis, for which he was operated several times. He presented with a three week history of headche. Initially, the headache was pressing, and at times throbbing, and is located across his forehead, and on top of his head. There was no associated fever, nausea, vomiting, photophobia, or phonophobia. One week later, the patient started to complain of blurry vision, along with diplopia. On physical examination, no general abnormalities were noted. Neurological examination revealed conscious, oriented thin male, with no obvious distress. His blood pressure was 110/70 mmHg, pulse 72/min, and temperature 36.9$^{o}$C. Meningeal irritation signs were negative. Cranial nerve examination showed evidence of bilateral paretic convergence squint with bilateral sixth nerve palsy, and normal fundus examination. The rest of the neurological examination was unremarkable. Lumbar puncture revealed an opening pressure of 180mm of cerebrospinal fluid (CSF), 5 white blood cells, 2000 red blood cells (traumatic tap), protein 79mg, sugar 68mg (simultaneous blood sugar 89mg). Magnetic resonance imaging was performed and showed fluid level in the axial T2 weighted images (Fig1), and significant mucosal enhancement of the sphenoidal sinus in the axial T1 weighted images (Fig 2). Patient was managed with rocephine, flagyl, and lincocin. The headache was markedly improved 3 days after of the start of treatment, and after 4 weeks his ocular movements were back to normal.

Discussion. The sphenoid sinus develops after age two, and starts to pneumatize at age eight. The frontal and sphenoid sinuses become clinically important in the teens, and frequently become infected in pansinusitis. The sphenoidal sinus drains into the sphenoethmoidal recess, and is contained within the body of the sphenoid bone deep in the nasal cavity and is divided in half by the

From the Department of Neurology (Mubaidin), Department of Radiology (Hiari), King Hussein Medical Centre, Amman, Jordan.

Received 10th April 1999. Accepted for publication in final form 26th May 1999.

Address correspondence and reprint request to: Dr Ammar F, Mubaidin, Consultant Neurologist, King Hussein Medical Centre, PO Box 926442, Amman 11110, Jordan. Tel. 585 6856. E-mail. Anoud@hotmail.com

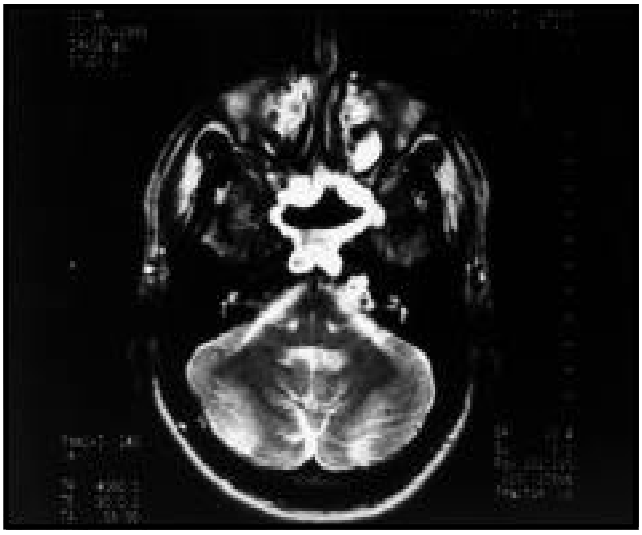

**Figure 1 -** T2W axial image showing hyperintense signal in the sphenoid sinus and air fluid level in it.

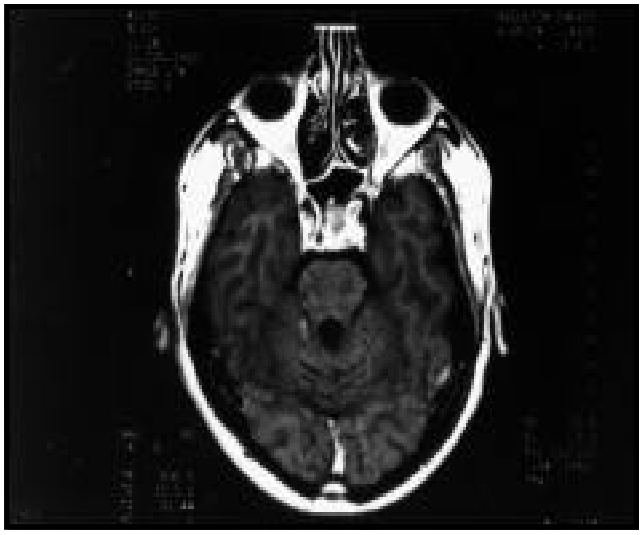

**Figure 2 -** Axial TW image after intravenous contrast enhancement, showing significant mucosal enhancement in the sphenoid sinus.

intersphenoidal septum. Each sinus communicates with the sphenoethmoidal recess, located at the posterior superior aspect of the superior concha. The roof of the sphenoid sinus is related to the middle cranial fossa and the pituitary gland in the sella turcica; lateral is the cavernous sinus; posteriorly is the clivus and pons; anteriorly the posterior nasal cavity, posterior ethmoid cells, and cribriform plate; and inferiorly the nasopharynx. The sphenoid walls can be extremely thin, and sometimes the sinus cavity is separated from the adjacent structure by just a thin mucosal barrier. Because of the close proximity to the cortical venous system, cranial nerves, and meninges, infection may spread to these structures and present as a central nervous system (CNS) infection or neurologic catastrophe.[1,2] The International Headache Society has established criteria for acute sinus headache.[3] To qualify as acute sinus headache, there must be purulent discharge, abnormal neuroimaging, and simultaneous onset of headache and sinusitis. These criteria may not be valid for sphenoid sinusitis, however, as purulent discharge is often lacking, and headache may precede sinus drainage. The sphenoid sinus develops after age two, and starts to pneumatize at age eight. The frontal and sphenoid sinuses become clinically important in the teens, and frequently become infected in pansinusitis. Sphenoid sinusitis is frequently misdiagnosed, since the sphenoid sinus is not accessible to direct clinical examination even with the flexible endoscope and is not adequately visualized with routine sinus x-rays.[4] While sphenoid sinusitis is an uncommon cause of headache, it is potentially associated with significant morbidity and mortality and requires early identification and aggressive management.[1,4,5] Headache is the most common symptom of acute sphenoid sinusitis. It is present in all patients. It is aggravated by standing, walking, bending, or coughing; it often interferes with sleep, and it is poorly relieved by analgesia. Its location is variable: vertex headache is rare; frontal, occipital, or temporal headache or a combination of these locations are most common. Periorbital pain is common. This is in contrast to the common teaching that retro-orbital or vertex headache is the most common presenting symptom of sphenoid sinusitis.[1,4,5,6-8] Fever occurs in over one half the patients with acute sphenoid sinusitis. The clinical features of a severe, intractable, new-onset headache that interferes with sleep and is not relieved by simple analgesics should alert one to the diagnosis of sphenoid sinusitis. Headache increases in severity with time and has no specific location. Pain or paresthesias in the facial disturbance of the 5th nerve and photophobia or eye tearing are suggestive of sphenoid sinusitis.[1,4,5,7-9] While Staphylococcus aureus is an infrequent cause of maxillary sinusitis, it is the major cause of acute sphenoid and frontal sinusitis. Isolated sphenoid sinusitis is rare.[10,11] Sinusitis is generally more common in children than adults, while frontal and sphenoid sinusitis are rare in children. In the pre-antibiotic era the sphenoid sinus was involved in up to 33% of cases of sinusitis. Today its incidence is about 3%.[1] The physical examination may not be helpful, particularly in sphenoid sinusitis. Not all patients are febrile, and

sinus tenderness is not always present. Neuroimaging (CT or MRI) is necessary to definitively diagnose sphenoid sinusitis, because plain x-rays are non-diagnostic in about 26% of cases.[4] Although diagnostic endoscopy with the flexible fiberoptic rhinoscopy allows direct visualization of the nasal passages and sinus drainage areas; sphenoid sinusitis is an exception to this generalization. Complication of sinus infection include bacterial meningitis, cavernous sinus thrombosis, subdural abscess, cortical vein thrombosis, ophthalmoplegia, and pituitary insufficiency.[1,2,4,5] In addition, sphenoid sinusitis can present as an aseptic meningitis due to the presence of a parameningeal focus.[12] Osteomyelitis, and subperiosteal abscess, visual loss mimicking optic neuritis, multiple cranial nerve palsies, or papilledema can also occur as a complication of sphenoidal sinusitis. Orbital complications, including edema, orbital cellulitis, and orbital abscess may occur. Thus, sinusitis can be a life-threatening condition and if neglected or mismanaged can lead to intracranial complications.[13] Sphenoid sinusitis without complications may be managed with high-dose intravenous antibiotics and topical and systemic decongestants for 24 hours.[4,5] If the fever (if present) and the headache do not start to improve or if any complications are present or develop, sphenoid sinus drainage is indicated.[14] Nevertheless, not all patients with headache improve, since some patients treated with functional endoscopic surgery for chronic sphenoidal sinusitis continued to have headaches postoperatively despite CT documented absence of sinus disease.[15] This suggests that the headache and sinusitis were coincident unrelated conditions.

## References


1. Lew D, Southwick FS, Montgomery WW, Weber AL, Baker AS. Sphenoid sinusitis: a review of 30 cases. N Engl J Med 1983; 19: 1149-54.
2. Sofferman RA. Cavernous sinus thrombophlebitis secondary to sphenoid sinusitis. Laryngoscope 1983; 93: 797-800.
3. Headache Classification Committee of the International Headache Society. Classification and diagnostic criteria for headache disorders, cranial neuralgia, and facial pain. Cephalalgia 1988; 8(Suppl 7): 1-96.
4. Goldman GE, Fontanarosa PB, Anderson JM. Isolated sphenoid sinusitis. Am J Emerg Med 1993; 11: 235-8.
5. Kibblewhite DJ, Cleland J, Mintz DR. Acute sphenoid sinusitis: management strategies. J Otolaryngol 1988; 17: 159-63.
6. Urquhart AC, Fung G, McIntosh WA. Isolated sphenoiditis: a diagnostic problem. J Laryngol Otol 1989; 103: 526-7.
7. Nordeman L, Lucid E. Sphenoid sinusitis, a cause of debilitating headache. J Emerg Med 1990; 8: 557-9.
8. Deans JAJ, Welch AR. Acute isolated sphenoid sinusitis: a disease with complications. J Laryngol Otol 1991; 105: 1072-4.
9. Turkewitz D, Keller R. Acute headache in childhood: a case of sphenoid sinusitis. Pediatr Emerg Care 1987; 3: 155-7.
10. Reilly JS. The sinusitis cycle. Otolaryngol Head Neck Surg 1990; 103: 856-62.
11. Kennedy DW. Surgical update. Otolaryngol Head Neck Surg 1990; 103: 884-6.
12. Brook I, Overturf GD, Steinberg EA, Hawkins DB. Acute sphenoid sinusitis presenting as aseptic meningitis: a pachymeningitis syndrome. Int J Pediatr Otorhinolaryngol 1982; 4: 77-81.
13. Singh B, VanDellen J, Ramjettan S, Maharaj TJ. Simogenic intracranial complications. J Laryngol Otol 1995; 109: 945-50.
14. Druce HM. Adjuncts to medical management of sinusitis. Otolaryngol Head Neck Surg 1990; 103: 880-3.
15. Gilain L, Aidan D, Coste A, Peynegre R. Functional endoscopic sinus surgery for isolated sphenoid sinus disease. Head Neck 1994: 16; 433-7.