

Case Report

# Neurobrucellosis

*Bindiganavale N. Gokul, MBBS, MD, Alfred Paul, MBBS, MD, Iftikhar Hussein, MBBS, MCPS.*

---

## ABSTRACT

Brucellosis, which is endemic in Saudi Arabia, can present as a disease with multisystem involvement. Occasionally the organisms invade the central nervous system producing varied neurological manifestations. Often the clinical diagnosis of neurobrucellosis is not straight forward and is obscure. Certain criteria have to be fulfilled for the definitive diagnosis of neurobrucellosis. We report 2 cases of neurobrucellosis which were encountered for the first time during the past 10 years at this hospital.

**Keywords:** Neurobrucellosis, neurological complications, brucellosis.

Neurosciences 2000; Vol. 5 (3): 182-185

---

**B**rucellosis is a zoonotic disease, transmitted from animals to man. Human brucellosis is caused mainly by 4 species belonging to the genus brucella. These are *Brucella melitensis*, *Brucella abortus*, *Brucella suis* and *Brucella canis*. The most severe form of human brucellosis is caused by *Brucella melitensis*. Brucellosis is endemic in Saudi Arabia and unfortunately the predominant species responsible is *Brucella melitensis*.<sup>1,2</sup> However the incidence of brucellosis in recent years is rapidly decreasing due to the tremendous development of health care facilities, immunization of sheep and cattle and the general improvement of health standards.<sup>1</sup> The most common mode of transmission of brucellosis is by consumption of raw milk or its products or consumption of raw or under cooked liver and meat or contact with animals especially sheep or goats.<sup>3</sup> Brucellosis can present with protean manifestations with a wide array of symptoms. Occasionally brucellae can invade the central nervous system, sometimes leading to permanent neurological deficits if treatment is not initiated promptly. For this, early diagnosis based on clinical acumen and laboratory confirmation is mandatory. Neurobrucellosis can present in various forms.<sup>2</sup> We report 2 cases of neurobrucellosis both of which had some unique features.

## Case Report.

**Patient 1.** A 24 year old Saudi female was seen in the Emergency Room (ER) for complaints of headache and vomiting, loss of appetite and lack of interest in her surroundings. Initially her symptoms began as a headache, 4 days later she complained of pain in the eyes, vomiting on and off and loss of appetite. There was a questionable history of fever. The headache persisted and was not relieved by analgesics. At this stage all the laboratory investigations were within normal limits. Serology for brucella was negative. Five weeks from the onset of her complaints she was admitted. The headache was now severe in intensity and associated with loss of appetite and vomiting. The patient also showed disinterest in her surroundings and preferred lying undisturbed in bed, not talking to relatives. On examination she was afebrile, lethargic, with stable vital signs. Her blood pressure (BP) was 130/90 mmHg, heart rate 84/min and respiratory rate 24/min. She exhibited photophobia, had neck stiffness and lay curled up in bed resenting examination and not responding to commands though conscious. Heart and lungs were clinically normal. She was admitted with a provisional diagnosis of "Headache for investigation"? Neurobrucellosis? Meningo-

---

From the Department of Microbiology (Gokul), Department of Medicine (Paul) and Department of Hematology (Hussein), Midhnab General Hospital, Al-Midhnab, Al-Qassim, Kingdom of Saudi Arabia.

Published with special permission from Saudi Medical Journal.

Address correspondence and reprint request to: Dr. B. N. Gokul, Microbiologist, Chief of Laboratory & Blood Bank, Midhnab General Hospital, PO Box 253, Al-Midhnab, Al-Qassim. Tel. +966 (6) 342 2206. Fax. +966 (6) 342 1325.

encephalitis. All routine laboratory investigations were within normal limits. Hemoglobin (Hb) 12.6 gm/dl. White blood cell count (WBC) 4800/mm<sup>3</sup>, platelets 238,000/mm<sup>3</sup>, sugar 98mg/dl, urea 11 mg/dl, creatinine 0.7 mg/dl, sodium 134 mEq/L, potassium 3.7 mEq/L, calcium 9.3 mg/dl, aspartate aminotransferase (AST) 19 IU/L, Serum alanine (ALT) 14 IU/L, Alkaline Phosphatase 96 IU/L and bilirubin 0.6 mg/dl. The next morning a lumbar puncture was carried out. The cerebro spinal fluid (CSF) was clear but under tension. Analysis revealed a cell count of 130/mm<sup>3</sup> with 96% lymphocytes and 4% neutrophils, sugar 43mg/dl (simultaneous blood sugar 110 mg/dl) and protein 132 mg/dl. A computerized tomography (CT) of brain was also arranged urgently. It was reported normal. Brucella serology in both serum and CSF was positive with a titre of 1:160. Blood and CSF culture did not reveal any growth. Once the diagnosis was established, treatment was commenced with Injection of Streptomycin 1.0 gm daily, Tetracycline 500 mg 4 times a day and Rifampicin 600 mg once daily. Within 48 hours the patient was relieved of her headache and photophobia and was able to sit up in bed, talk normally and eat her food. She also began to walk. She completed an 8 week course of treatment and was reviewed in the clinic a month later when she was found to be perfectly well.

**Patient 2.** A 38 year old Indian male was admitted through the ER for the complaints of frequent vomiting and headache of a weeks duration associated with loss of appetite, general weakness, tiredness and ill-health. At admission the patient was found to be lethargic, disinterested in his surroundings and was not answering questions correctly. He was febrile and the only positive clinical finding was a stiff neck. There was no focal neurological deficit and no other abnormal central nervous system findings. Heart, lungs and abdomen were clinically normal. The same day a lumbar puncture was carried out and the fluid was clear, not under tension and the analysis revealed 150 cells/mm<sup>3</sup>, all lymphocytes, protein 174 mg/dl and sugar 43 mg/dl (simultaneous blood sugar 84 mg/dl). Cerebrospinal fluid and blood culture did not yield any growth. Other routine lab works were non contributory. His Hb was 16.9 gm/dl, WBC 7100/mm<sup>3</sup>, erythrocyte sedimentation rate of 20 mm in the first hour, platelets 220,000/mm<sup>3</sup>, urea 55 mg/dl, creatinine 1.6 mg/dl, sodium 143 mEq/L, potassium 4.0 mEq/L, brucella agglutination test and Widal test for enteric fever were negative. Keeping in mind that the patient is an Indian, the possibility of tuberculous meningitis was entertained. However, patient was managed symptomatically. His condition did not show any improvement. He continued to be febrile, vomited frequently, had total loss of appetite for both solids and liquids and appeared distanced from his surroundings. Smear for malarial parasite

was requested thrice at the height of temperature but was always negative. Blood and urine cultures were negative. Sinus x-ray, chest x-ray and thoracolumbar spine x-rays (as the patient also complained of back pain over the dorsal vertebrae) were also carried out and reported normal. Since the patient was not eating anything, he became very weak and found it difficult to walk, but there were no neurological findings. A CT of brain was also carried out and was reported normal. Lumbar puncture and brucella agglutination test were repeated after a week. The titre was 1:640 in serum and 1:160 in CSF. Other CSF analyses were as follows; sugar 21 mg/dl (simultaneous blood sugar 80 mg/dl), cells 108/mm<sup>3</sup> all lymphocytes, protein 66 mg/dl and culture revealed no growth. His renal and liver functions were normal, urea 19 mg/dl, creatinine 1.5 mg/dl, uric acid 4.9 mg/dl, sodium 138 mEq/L and potassium 4.4 mEq/L. Aspartate aminotransferase 64 IU/L, ALT 35 IU/L, Alkaline Phosphatase 132 IU/L, bilirubin 1.0 mg/dl, total protein 6.5 gm/dl and albumin 3.7 gm/dl. Ultrasound of the abdomen was unremarkable. There was no organomegaly. The patient was started on injection of Streptomycin 1.0 gm daily, Cotrimoxazole twice daily and Doxycycline 100 mg twice daily. Fever and vomiting continued unabated for a week after which his temperature settled to a normal level. However vomiting and loss of appetite persisted. Liver function tests were repeated and were normal. Keeping the possibility of drug induced vomiting in mind, Doxycycline was replaced with Rifampicin 600 mg daily. After a couple of days, vomiting decreased but still occurred on and off. The patient continued to have a poor appetite with total disinterest for food. He was managed with IV fluids. As the patient developed a total lack of interest in food compounded by intermittent vomiting, he became very weak, emaciated and hypotensive if mobilized. Various symptomatic and supportive therapeutic measures were tried but were unsuccessful. Finally it was decided to obtain a psychiatric consultation. The psychiatrist advised antidepressive treatment with Amitriptyline, this was commenced. Meanwhile a femoral catheter was inserted and the patient given lipofusion and other nutrients to compensate his poor intake. Slowly things began to change for the better, his appearance improved, the vomiting decreased significantly and he started taking an interest in his surroundings and food. The patient received an 8 week course of treatment and was kept a while longer in order to improve his general condition and make him fit for discharge. When it was decided that the patient had improved sufficiently and would be able to manage on his own if discharged, he was sent home after a stay in the hospital of 60 days. He was later followed up in the clinic on 2 occasions when he was found active, normal and free of any symptoms.

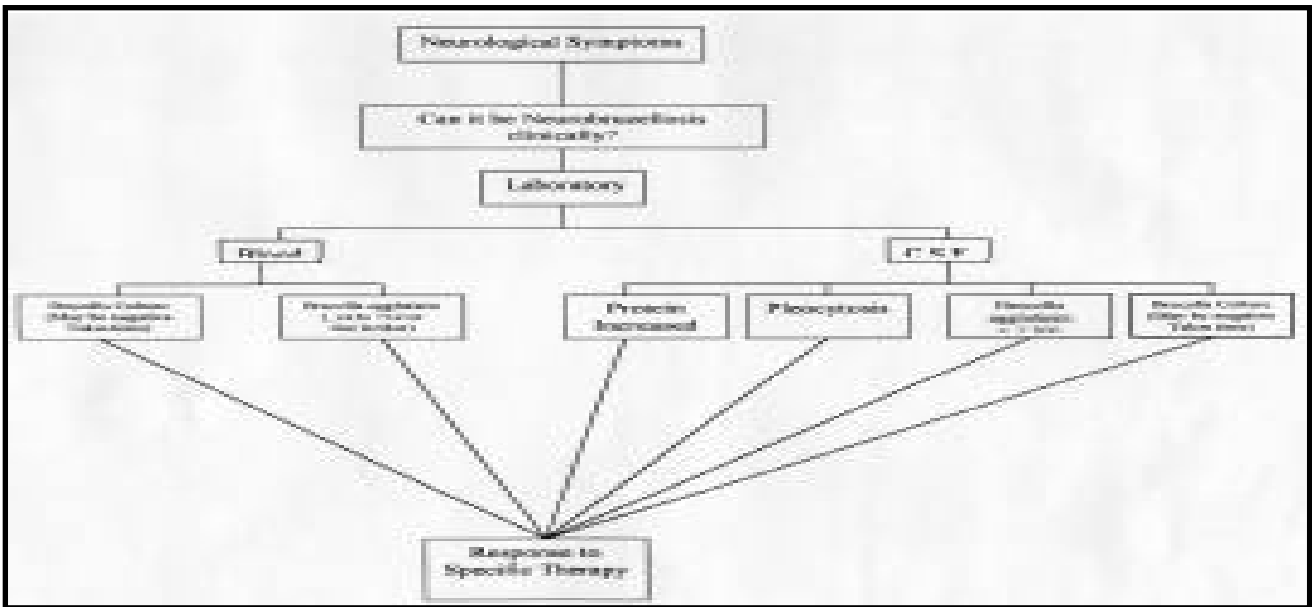
**Discussion.** Neurobrucellosis is an occasional complication of brucellosis. In a study by Omar et al, among children, they reported less than one percent involvement of the nervous system in brucellosis cases.<sup>4</sup> Usually brucellosis is diagnosed promptly either by a rising titre of agglutinins in the serum or by isolating the organisms from blood culture. But culture results are delayed because of the prolonged period of incubation necessary for its growth and often are negative. The specific diagnosis of neurobrucellosis however poses some problems because of its obscure presentation. This is especially so in cases of persons coming from non-endemic areas. The first case, a Saudi female presented repeatedly with vague complaints and for a while the possibility of psychiatric illness was also considered. Such presentations in neurobrucellosis are reported. The second case, an Indian male who had been working in this country for 5 years also presented with atypical symptoms. Coming from an area where tuberculosis is endemic, the possibility of tuberculous meningitis was also entertained. The definitive diagnosis in such cases is a matter of conjecture. Seroconversion from brucella agglutinin negative to a titre of 1:160 in the first case and 1:640 in the second case and detection of agglutinins in CSF assumes a significant diagnostic value.

Al-Deeb and Yaqub have suggested certain criteria for the definitive diagnosis of neurobrucellosis.<sup>5</sup> These include, unexplainable neurological dysfunction but clinically compatible with Neurobrucellosis, lymphocytic pleocytosis and increased protein in CSF, positive CSF culture or agglutinin titres of 1:160 or more in CSF and prompt

**Table 1 -** Showing the similarity in the 2 Neurobrucellosis cases.

	Patient 1	Patient 2
<b>Clinical:</b>		
Fever	?+	+
Headache	+	+
Vomiting	+	+
Loss of appetite	+	+
<b>Laboratory:</b>		
Serum brucella agglutinin	+	+
CSF Pleocytosis	+	+
CSF Protein	Increased	Increased
CSF Brucella agglutinin	+	+
Blood/CSF culture	-	-
CSF - cerebrospinal fluid		

response to anti brucella chemotherapy both clinically and in laboratory findings (Figure 1). Evaluation of CSF IgG index will demonstrate the synthesis of antibodies intrathecally.<sup>2</sup> Detection of C-reactive protein in CSF has been described as one of the parameters for rapid identification of pyogenic meningitis from other types of central nervous system infections and disorders.<sup>6,7</sup> But in these studies neurobrucellosis was not included. However, in both our cases CSF-CRP was negative and all the above mentioned criteria were fulfilled (Table 1). The majority of cases of brucellosis present as fever of unknown origin until proved either by serum antibody levels or by culture. Our first patient was



**Figure 1 -** Diagram showing the steps in the diagnosis of Neurobrucellosis.

afebrile throughout the course of the disease. The second patient needed psychiatric consultation and had to be treated with antidepressants for his recovery. Both of them recovered uneventfully without any residual neurological deficits. Recommended therapy for Neurobrucellosis includes simultaneous administration of any 3 of the following drugs: Doxycycline, Rifampicin, Streptomycin, Co-trimoxazole, Ceftriaxone or Ciprofloxacin.<sup>8</sup> We managed our patients with a combination of Rifampicin, Streptomycin, Co-trimoxazole and Tetracycline/Doxycycline. The treatment in neurobrucellosis should be continued for a minimum period of 8 weeks. Though the incidence of neurobrucellosis is not frequent, one should keep one's mind open to identify neurobrucellosis clinically and confirm with laboratory investigations to initiate prompt and recommended therapy. This will not only reduce the morbidity but also gives the patient a chance to recover without any permanent deficits. During the past decade, according to our laboratory records, there has been a steady decline of brucellosis. This fact is also substantiated by other local reports.<sup>9</sup> Indeed, with such extraordinary advancement in health care system and general awareness, brucellosis can be eradicated from this country.

**Acknowledgment.** The authors thank Ms. Suja Issac for her excellent secretarial assistance.

## References

1. Panayiotopoulos CP. Neurobrucellosis: A cause for concern and action [Editorial]. *Annals of Saudi Medicine* 1988; 8: 167-168.
2. Hudgson P, Al-Bunyan MA. Polyradiculoneuropathy and Cranial Nerve involvement in Brucellosis. *Proceedings of the Symposium on Neurobrucellosis*; 1988 Jan 26; Riyadh, KSA. *Annals of Saudi Medicine* 1989; 9: 220-232 (Supplement).
3. Benjamin B, Annobil SH. Childhood brucellosis in southwestern Saudi Arabia: a 5 year experience. *J Trop Pediatr* 1992; 38: 167-172.
4. Omar FZ, Zuberi S, Minns RA. Neurobrucellosis in childhood: six new cases and a review of the literature. *Dev Med Child Neurol* 1997; 19: 762-765.
5. Al Deeb SM, Yaqub B. Neurobrucellosis. *Post Graduate Doctor (ME)* 1994; 17: 470-474.
6. Gokul BN, Chandramuki A, Rajendran R, Sreenivasa Babu PR. Detection of C-Reactive Protein in cerebrospinal fluid for rapid diagnosis and differentiation of pyogenic meningitis from other diseases of central nervous system. *Neurology India* 1989; 37: 23-29.
7. Abramson JS, Hampton KD, Babu S, Wasilaus BL, Marcon MJ. The use of C-reactive protein from cerebrospinal fluid for differentiating meningitis from other central nervous system diseases. *Journal of Infectious Diseases* 1985; 151: 854-858.
8. Akdeniz H, Irmak H, Anlar O, Demiroz AP. Central nervous system brucellosis: presentation, diagnosis and treatment. *J Infect* 1998; 36: 297-301.
9. Al-Khowaiter IM, Al-Daiel TQ, Abukhamsin J, Ratard RC. In: *PM notes*. KSA: Saudi Aramco Medical Services Organization; 1997.