

# Diabetic Neuroarthropathy

Shakeel A. Qidwai, D.Orth, M.S.Orth, M. A. Salam Khan, MBBS, D.Neuro, Syed R. Hussain, MRCP,  
Mohiuddin S. Malik, D.Orth.

---

## ABSTRACT

**Objective:** This study was undertaken to assess the incidence of diabetic neuroarthropathy and its related morbidity.

**Methods:** The medical records of 296 diabetic patients were analyzed retrospectively between June of 1998 and July of 1999. The patients with long standing, poorly controlled diabetes mellitus and associated peripheral neuropathy were evaluated clinically and radiographically for the presence of arthropathic changes in the feet. Clinically, neuropathy was considered if there was absence of ankle jerk or glove and stocking sensory loss, or both. Radiographically, the presence of stress fractures, dislocation/subluxation, lytic or arthritic lesions of the bone and joints were taken as indicative of the disease. They were treated conservatively by total contact casting or surgically in the form of ray excision, amputation and skin grafting. They were followed up for an average period of 13 months. Results were evaluated clinically and radiographically.

**Results:** The maximum incidence of diabetes mellitus

was in the age group of 41-80 years. Diabetic neuropathy was present in 37 patients (12.5%). Male to female ratio was 23:14 with an average age of 70.42 years. The mean duration of diabetes mellitus was 14.2 years. Seventeen feet in 11 patients (4%) were found to have diabetic neuroarthropathy. The joints involved were tarsometatarsal (76%), metatarsophalangeal (59%), subtalar (47%) and interphalangeal joints (41%). Two patients underwent foot amputations. Patients treated with total contact casting resulted in satisfactory progress.

**Conclusion:** Diabetic neuroarthropathy, a less recognized complication of diabetes mellitus needs greater attention in Saudi Arabia. High-risk feet should be subjected to routine radiographs or preferably a computerized tomography examination. The timely detection of this problem can save many patients from disastrous complications.

**Keywords:** Diabetic foot, neuroarthropathy, charcot foot

**Neurosciences 2001; Vol. 6 (2): 118-121**

---

Neuropathic (charcot) osteoarthropathy is a non-infective, destructive lesion of the bone and joint, in a patient who has peripheral neuropathy.<sup>1</sup> It develops most often in weight bearing joints. Diabetes mellitus (DM) is the most common cause in the United States, the reported incidence is 0.1% (1/800) in diabetic patients.<sup>2</sup> The same incidence was reported by Naghmi in 1998.<sup>3</sup> Due to improvements in the management of DM, diabetic patients are living longer. Therefore, neuropathic arthropathy, a late effect of peripheral neuropathy of the foot and ankle, continues to be a problem frequently seen in Orthopedic practice.<sup>1</sup> It has been estimated that 20%

of all diabetic admissions to the hospital are for lesions of the foot.<sup>4</sup> Diabetes mellitus has emerged as a major public health problem in Saudi Arabia, demanding effective strategies for prevention, detection and management. Although most of the aspects of the disease have been described, the pattern of diabetic foot lesions has not been documented satisfactorily. Sulaimani et al<sup>5</sup> reported a 15% incidence of neuropathic foot in Saudi Arabia. In a more recent report, the incidence of symptomatic diabetic neuropathy has been described to be 56% by Akbar et al.<sup>6</sup> The lesions characteristically occur in patients with long-

---

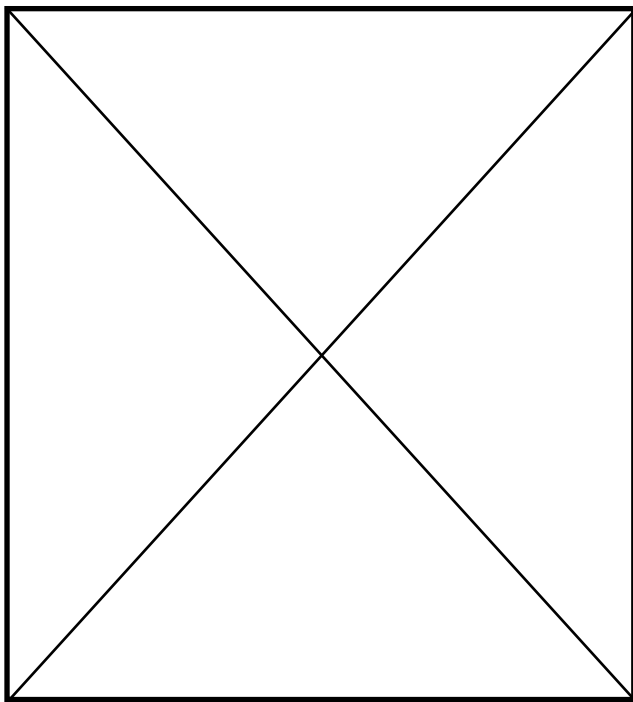
From King Khalid Hospital, Najran, Kingdom of Saudi Arabia.

Published with special permission from Saudi Medical Journal.

Address correspondence and reprint request to: Dr. S. A. Qidwai, C/O Prof. Z. U. Ahmad, 4-389 Noor Bagh, Dodhpur, Aligarh, UP India. Tel. +91 (571) 403715.

standing and poorly controlled diabetes. The presentation varies from involvement of the joints of the foot, to stress fractures and osteolytic lesions of the bone. This study is a retrospective analysis of a series of patients with DM with neuroarthropathic changes seen at King Khalid Hospital (KKH) Najran. The pathogenesis of the disease is presented in the algorithm (Figure 1).

**Methods.** The medical records of 296 diabetic patients seen between June of 1998 and July of 1999 were retrospectively analyzed to ascertain the incidence of diabetic neuroarthropathy. The criteria for inclusion of the patients in this study was: 1. Patients with long-standing DM, usually over 10 years 2. Poorly controlled DM/drug defaulters. 3. Presence of diabetic neuropathy: clinically assessed by the absence of ankle jerk, and glove and stocking sensory loss. 4. Presence of foot deformity, limited foot movements. 5. Presence of trophic ulcers, swelling and tenderness or soft tissue abscess formation in the foot. Conventional apical plane (AP) and lateral radiographs of the foot were carried out and studied for the presence of lytic bony changes or arthritic changes at the ankle, subtalar (ST) joint, tarsometatarsal (TM) joint, metatarsophalangeal (MP) joint and interphalangeal (IP) joint. The affected feet were treated by conservative and surgical methods. Patients showing early changes were treated by total contact cast



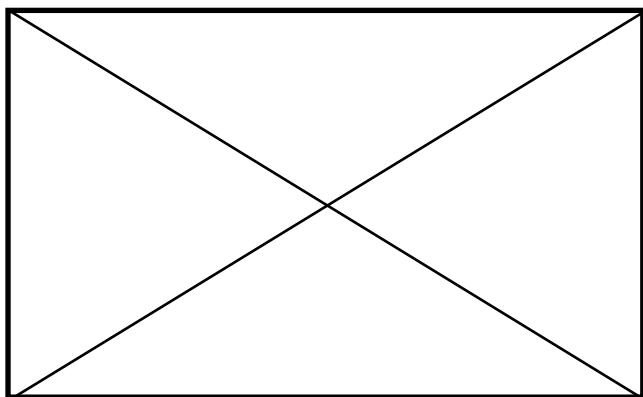
**Figure 1** - Algorithm explaining the pathophysiology of the diabetic Charcot foot.

**Table 1** - Age incidence of diabetes mellitus.

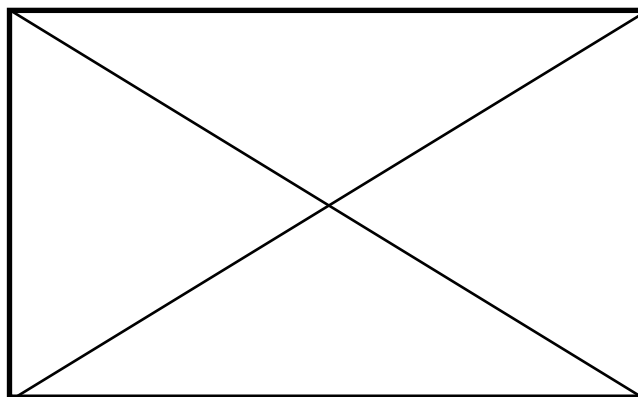
Age interval (years)	Number of patients	Percentage %
0-20	14	5.0
21-40	40	13.5
41-60	120	40.5
61-80	122	41.0
<b>TOTAL</b>	<b>296</b>	<b>100.0</b>

(TCC) and non-weight bearing mobilization for 2-3 months until the healing of the bony lesion. These patients were kept under surveillance by regular follow up in the clinic. They were also advised on general care of the foot: to avoid trauma to the foot, tight shoes, moisture and regular foot baths with antiseptic lotion. The surgical treatment consisted of ray amputation in one patient, amputation of the foot in 2 patients and skin grafting for the ulcer in 2 patients. The need for reconstructive surgery in the form of osteotomy, arthrodesis and internal fixation did not arise. The results were assessed clinically with the improvement in blood sugar levels, healing of soft tissue lesions and improvement in the movements of the joints of the foot. Radiographically, the results were assessed with the healing of bone and joint lesions or the arrest in the progression of deformity.

**Results.** A total of 296 diabetic patients were studied, with a male/female ratio of 178:118, ranging between 11-80 years of age. The maximum incidence of DM was between 41-80 years (Table 1). Diabetic neuropathy was present in 37 (12.5%) patients. Nineteen patients were on insulin therapy while the rest of the patients were on oral hypoglycemic drugs. There were 23 male and 14 female patients with the average age of 70.42 years (range, 40–80 years). The mean duration of diabetes was 14.2 years (range, 10-7 years). Twelve patients had associated nephropathy and retinopathy and one had pulmonic stenosis. The average random blood sugar was 15.01 mmol ranging between 9.3-28.9 mmol. Eight patients had trophic ulcers (Figure 2). Seventeen feet in 11 patients (4%) were found to have bone and joint lesions. The TM joint was involved in 13 feet (76%) followed by MP joint in 10 (59%), subtalar joint in 8 (47%), interphalangeal joint in 7 (41%) and ankle joint in 6 feet (35%). Stress fractures were present in 3 feet (18%). One patient had osteolysis of metatarsal bones without any sign of apparent infection (Figure 3). The patients treated with the TCC had a



**Figure 2** - Neuroarthropathic foot with trophic ulcers in high pressure areas.



**Figure 3** - Apical plane and lateral views of a diabetic neuropathic foot with distortion of multiple joints and osteolysis of the bone with a fracture.

satisfactory clinical and radiological improvement. They are still under observation and follow-up.

**Discussion.** Charcot arthropathy in long standing diabetics is a well-recognized complication.<sup>1-3</sup> There has been inconsistency in the reported incidence of neuroarthropathy in the diabetic foot. There is also a lack of agreement over the most commonly affected joint; the involvement of the MP joint has been greatly underestimated according to Scartozzi and Kanat.<sup>7</sup> Deformity of the foot and dysfunction of the lower extremity are debilitating complications of DM which often leads to a significant permanent disability. Deformities of the foot and ankle resulting from a neuropathic fracture or dislocation cause improper fitting of shoes and abnormal pressure on various parts of the plantar surface of the foot during weight bearing. These changes predispose the foot to ulceration in high-pressure areas (Figure 2), loss of plantigrade position of the foot and progression of the deformity.<sup>1</sup> In our study, the acute neuropathic changes (fractures, subluxations) subsided in a period of 2-3 months after treatment with TCC and non-weight bearing mobilization. This is almost similar to that reported by Sinacore.<sup>8</sup> He has reported an average healing time of 86+/-45 days. A high index of suspicion is required to detect the problem of charcot arthropathy in a diabetic neuropathic foot. The initial presentation of unilateral warmth and swelling in a neuropathic foot after an episode of minor trauma is suggestive of a developing Charcot joint. This can be easily misdiagnosed as cellulitis or gout.<sup>9</sup> Radiographs are often normal in early cases. Accurate radiographic evaluation of diabetic neuropathy is increasingly difficult. Griffith et al<sup>10</sup> reported an incidence of 75% bilateral neuroarthropathic changes following computerized tomography (CT) examination of 22

patients with diabetic neuropathy. The overall incidence of neuroarthropathy in the present study is 4% which is higher than reported by Naghmi (0.12%).<sup>3</sup> The incidence of this complication in patients with established neuropathy is 30% which could be more if the patients had undergone a CT examination or a Technicium bone scan. Typically the patients were middle aged or older, 57% were taking insulin, 32% had associated nephropathy and retinopathy and had had diabetes for more than 10 years. Almost similar findings were reported by Cofield et al.<sup>11</sup> Various reconstructive procedures have been recommended to maintain a plantigrade foot.<sup>1,12</sup> Early and Hansen<sup>12</sup> performed fusion of collapsed joints using internal fixation to restore the shape in 21 diabetic feet. The average time to radiographic union was 5 months. Improvement in the shoe fit and ambulatory status was noticed in 13 of 15 patients who had a successful reconstruction.<sup>12</sup>

In conclusion, DM has emerged as a major public health problem in Saudi Arabia. The problem of diabetic neuroarthropathy deserves greater attention to detect it at an earlier stage so as to prevent diabetic feet from further complications. High-risk feet should be subject to routine AP and lateral radiographs or preferably a CT examination. High-risk criteria are 1. Long standing DM > 10 years; 2. Poorly controlled DM; 3. Diabetic neuropathy and 4. DM with soft tissue foot lesions.

## References

1. Johnson JE, Missouri St L. Operative Treatment of Neuropathic Arthropathy of the Foot and Ankle. *J Bone Joint Surg* 1998; 80-A: 1700-1709.
2. Sinha S, Munichoodappa CS, Kozak GP. Neuroarthropathy (Charcot joints) in DM. *Medicine* 1972; 51: 191-210.
3. Naghmi R. Diabetic Neuroarthropathy. *The Practitioner* 1998; 9: 374-375.
4. Masson EA, Angle S, Roseman P. Foot Ulcers: Do Patients Know How To Protect Themselves? *Practical Diabetes* 1988; 426-428.

5. Sulaimani RA, Famuyiwa OO, Mekki MO. Pattern Of Diabetic Foot Lesions In Saudi Arabia: Experience From King Khalid Hospital, Riyadh. *Annals of Saudi Medicine* 1991; 1: 47-50.
6. Akbar DH, Mira SA, Zawawi TH, Malibary HM. Subclinical Diabetic Neuropathy: A Common Complication In Saudi Diabetics. *Saudi Med J* 2000; 21: 433-437.
7. Scartozzi G, Kanat I. Diabetic Neuroarthropathy Of The Foot And Ankle. *J Am Podiatry Assoc* 1990; 80: 298-303.
8. Simacore DR. Acute Charcot Arthropathy In Patients With Diabetes Mellitus; Healing Time By Foot Location. *J Diabetes Complications* 1998; 12: 287-293.
9. Edmonds ME. The Diabetic Foot: Pathophysiology And Treatment. *J Clin Endocrinol Metab* 1986; 15: 889-916.
10. Griffith J, Davies AM, Close CF, Natrass M. Organized Chaos? Computed Tomographic Evaluation Of The Neuropathic Diabetic Foot. *Br J Radiol* 1995; 68: 27-33.
11. Coffield RH, Morrison MJ, Beabout JW. Diabetic Neuroarthropathy In The Foot: Patient Characteristics And Patterns Of Radiographic Change. *Foot Ankle* 1983; 4: 15-22.
12. Early JS, Hansen ST. Surgical Reconstruction Of The Diabetic Foot: A Salvage Approach For Midfoot Collapse. *Foot Ankle Int* 1996; 17: 325-330.