

Goldenhar syndrome and hereditary tyrosinemia type 1

Moeen A. Al-Sayed, MD, FAAP, Ali M. Al-Asmari, MD, Mohammed S. Rashed, PhD.

ABSTRACT

We report a case of Goldenhar syndrome and hereditary tyrosinemia type 1 (HTT1), to our knowledge an association not previously described. This case further increases the diversity of observations and clinical descriptions of patients with this complex syndrome. We discuss pathogenetic aspects, and demonstrate further evidence of the effectiveness of 2-(2-nitro-4-trifluoromethyl benzoyl)-1,3-cyclohexanedione in the treatment of HTT1.

Neurosciences 2003; Vol. 8 (1): 55-59

Goldenhar et al¹ described a syndrome characterized by ocular, auricular, skeletal defects, and other orofacial and extracephalic anomalies. The disorder has a wide range of phenotypic expression, and a variety of terms have been used to describe the condition including: hemifacial microsomia, first arch syndrome, first and 2nd branchial arch anomalies, facioauriculovertebral syndrome, Goldenhar "syndrome" and otomandibular dysostosis. Gorlin et al² proposed joining the former terms together, and introduced the term oculoauriculovertebral spectrum (OAVS). The etiology and pathogenesis of this disorder are both complex and heterogenous. Most cases are sporadic, but many familial occurrences have been reported.³⁻⁸ Tyrosinemia type I (HTT1; McKusick 276700) is an autosomal recessive classic inborn error of metabolism, caused by the deficiency of fumarylacetoacetase, the last enzyme in tyrosine metabolism. Major organs involved are the liver, kidney and bones with the major clinical manifestations being progressive liver disease, cirrhosis, hepatocellular carcinoma, renal Fanconi syndrome, glomerulosclerosis and hypophosphatemic rickets. Succinylacetone (SA) presence in serum or urine is diagnostic for this condition.⁹

Before the introduction of 2-(2-nitro-4-trifluoromethylbenzoyl)-1,3-cyclohexanedione (NTBC), liver transplantation had been the ultimate treatment for over 10-years and the disease was associated with high morbidity and mortality.¹⁰ We report a case of Goldenhar syndrome associated with hereditary HTT1. The parents were first-degree relatives. To our knowledge, this association has not previously been described.

Case Report. The patient presented at 5 months of age with hepatosplenomegaly, ascites, clotting abnormalities and dysmorphic features following referral from a local hospital. She was the 5th child of a 30-year-old gravida 5, para 5 lady and her 33-year-old first cousin husband. Both parents were healthy. Two daughters were alive and well. One daughter died at 2-months of age of unknown cause, and a son died at the age of 10-months with HTT1. The pregnancy was normal with no history of exposure to medications or toxins. Delivery was complicated by cesarean section due to failure to progress. Apgar scores were 7 and 10 at one and 5 minutes. Birth weight was 3300 grams.

From the Department of Medical Genetics (Al-Sayed), Department of Genetics (Rashed), King Faisal Specialist Hospital and Research Centre and the Department of Pediatrics (Al-Asmari), Suleimaniah Children's Hospital, Riyadh, Kingdom of Saudi Arabia.

Published simultaneously with special permission from Saudi Medical Journal.

Address correspondence and reprint request to: Dr. Moeen A. Al-Sayed, Consultant Pediatrician and Geneticist, Department of Medical Genetics (MBC 58), King Faisal Specialist Hospital and Research Centre, PO Box 3354, Riyadh, 11211, Kingdom of Saudi Arabia. Tel. +966 (1) 4427763. Fax. +966 (1) 4427784. E-mail: moeen@kfshrc.edu.sa/alsayed_moeen@hotmail.com.

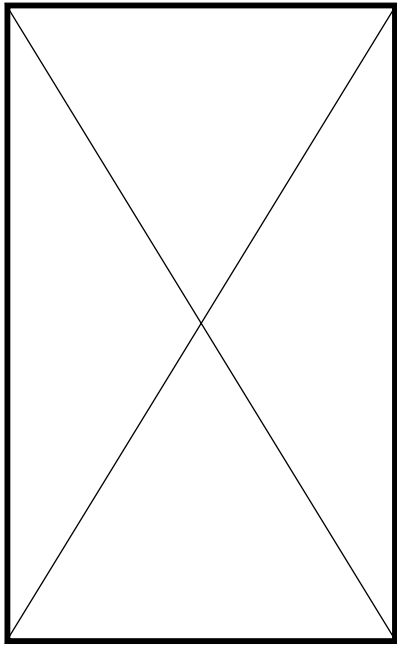


Figure 1 - Facial asymmetry and abdominal distension.

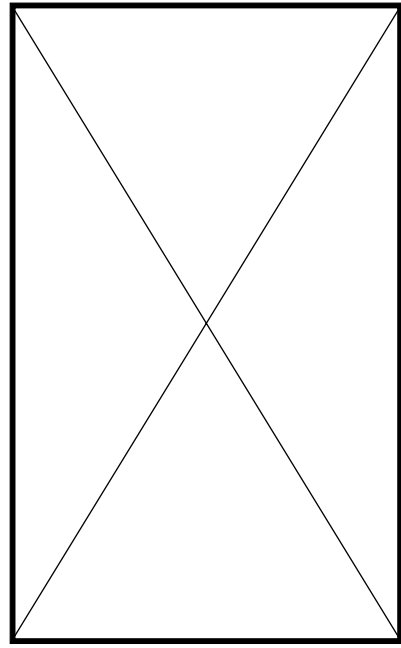


Figure 3 - Rudimentary round nodule replacing the left ear is noted. A small preauricular tag and thoracolumbar kyphosis are also evident.

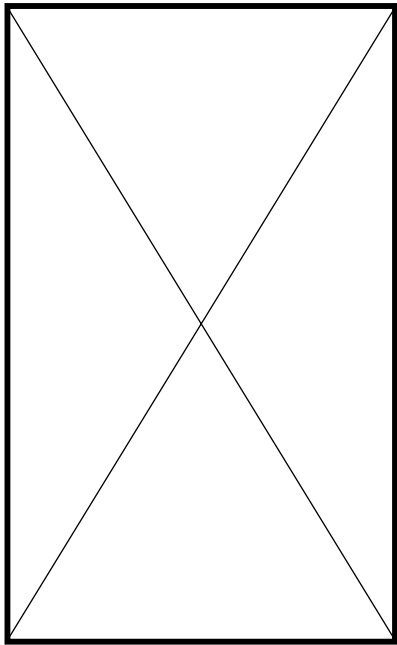


Figure 2 - Broad forehead, triangular face, hypertension, thin upper lip, macrosomia and left hemifacial microsomia are evident.

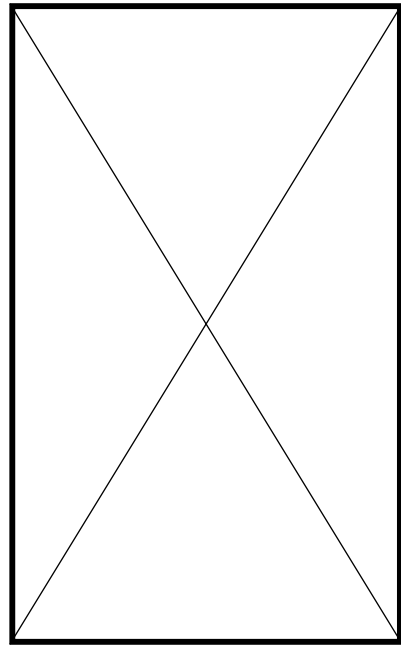


Figure 4 - Dysplastic right ear.

Except for dysmorphic features and thoracolumbar kyphosis, no abnormalities were noted at birth. From the age of 2-months, the parents noted progressive abdominal distension and jaundice. Clinical examination revealed a sick child with respiratory distress, deep jaundice, distended abdomen (**Figure 1**), hepatosplenomegaly and ascites. Dysmorphic features were mainly craniofacial and included, broad forehead, triangular face, hypertelorism, depressed nasal bridge, high arched palate with no cleft, very thin upper lips, macrostomia, pointy chin and left hemifacial microsomia (**Figure 2**). A rudimentary round nodule replaced the left ear and the left preauricular skin tag was present (**Figure 3**). Left external auditory canal was absent. The right ear was dysplastic with narrow right external auditory canal (**Figure 4**). Examination of the back revealed thoracolumbar kyphosis (**Figure 3**). Hands and feet were normal, and further examination failed to reveal any other malformations. Initial investigations revealed hypokalemia (2.9 mmol/L), hypophosphatemia (0.9 mmol/L), hyperbilirubinemia (151 mmol/L), thrombocytopenia and anemia. Coagulation profile revealed prolonged prothrombin time (40.9) and partial thromboplastin time (58.4). Plasma tyrosine (1019 mmol/L), phenylalanine (287 mmol/L), methionine (876 mmol/L) and α -fetoprotein (26921ug/l) were all elevated. Urine analysis revealed generalized aminoaciduria and proteinuria. Fractional tubular absorption of phosphate was 17%. Urine succinylacetone was elevated confirming the diagnosis of tyrosinemia. Computerized tomography of abdomen revealed hepatosplenomegaly, evidence of cirrhosis, nephromegaly and ascites. A skeletal survey revealed generalized lack of mineral, mild flaring of the metaphysis of long bones and gibbus at the lumbar one level with dysplastic appearance of a few lumbar vertebrae. Brain stem auditory evoked potentials were normal.

Dietary treatment and supplementation with oral calcium, phosphate and vitamin D3 was started. Treatment with NTBC was started soon after admission. The dose was increased gradually from 0.1-0.6-mg/kg body weight. During 3 months of follow-up after the start of NTBC, there was a steady improvement in the patient's condition both clinically and biochemically. The jaundice became lighter, appetite improved, abdominal distension regressed, liver and spleen size decreased and ascites disappeared. She became more active and interested in her surroundings. She started reaching for objects and transferring them between her hands. Biochemically, the hypokalemia, hypophosphatemia, hyperbilirubinemia, thrombocytopenia and anemia improved significantly. Plasma tyrosine, phenylalanine and methionine decreased steadily to near normal values. The coagulation abnormality improved, and the serum α -fetoprotein gradually declined. Urine succinylacetone secretion decreased to undetectable levels.

Discussion. Goldenhar syndrome or oculoauriculovertebral spectrum is a complex disorder that includes a variable combination of microtia, hemifacial microsomia, lateral cleft like extension of the corner of mouth (macrostomia), epibulbar dermoid, and vertebral anomalies. First and 2nd branchial arch structures are affected most frequently. There are no universally agreed upon minimal diagnostic criteria, however, according to Kumar et al,¹¹ the minimum criteria for the diagnosis of OAVS are the presence of 2 of the following abnormalities: otic hypoplasia, hemifacial microsomia, lateral facial cleft, epibulbar dermoid or upper eyelid coloboma and vertebral anomalies. Ear anomalies are considered to be a mandatory feature by some authors.¹² Our patient fulfilled the above criteria; bilateral microtia, hemifacial microsomia, macrostomia and vertebral anomalies were all present. The absence of upper eyelid coloboma and epibulbar dermoid is not surprising given the well-known variability in presentation of this disorder.²

We also discussed and dismissed several possibilities known to have overlapping features with OAVS. A number of chromosomal abnormalities have been associated with OAVS, including del (5p),¹³⁻¹⁵ del (6q)¹⁶ and many others. These were excluded by a normal karyotype. Other overlapping conditions including branchio-oto-renal syndrome and Towns-Brooks syndrome were easily excluded based on the lack of many features of these syndromes. Treacher Collins syndrome was also excluded based on the facial gestalt and lack of several features including colobomas of the lower eyelids, absence (partial or total) of lower eyelashes medial to the coloboma and cleft palate.

Casually, OAVS is considered heterogeneous and several theories have been suggested to explain the pathogenetic mechanisms of the various anomalies seen in OAVS. Early vascular disruption and formation of embryonic hematoma resulting in destruction of differentiating tissues in the first and 2nd branchial arch region were hypothesized by Poswillo.¹⁷⁻¹⁹ Defective blastogenesis, namely, the time referred to all stages of development during the first 4 weeks of gestation has also been suggested.²⁰ Diabetic embryopathy causes a variety of congenital malformations^{21,22} including craniofacial anomalies.²³⁻²⁹ More recently, it has been suggested that the teratogenic effects of maternal gestational diabetes probably include such craniofacial malformations as the oculoauriculovertebral/Goldenhar complex.³⁰ The pregnancy in our patient was complicated by mild gestational diabetes since it was controlled by diet only. However, based on the above reports, gestational diabetes cannot be excluded as a contributing factor.

Most cases of OAVS are sporadic, but familial instances have been reported.³⁻⁸ Both autosomal dominant, and autosomal recessive inheritance has been suggested to explain the familial occurrence. Consanguinity has been reported once in a single

sporadic case.³¹ Both parents were normal which makes autosomal dominant inheritance very unlikely. Although parents were consanguineous, autosomal recessive inheritance would be less unlikely given the negative family history. In addition, the odds of having 2 autosomal recessive diseases seems to be less unlikely.

Tyrosinemia type I (HTT1; McKusick 276700) is an autosomal recessive classic inborn error of metabolism, caused by the deficiency of fumarylacetoacetase, the last enzyme in tyrosine metabolism. Major organs involved are the liver, kidney and bones with the major clinical manifestations being; progressive liver disease, cirrhosis, hepatocellular carcinoma, renal Fanconi syndrome, glomerulosclerosis and hypophosphatemic rickets. These manifestations are thought to be secondary to the accumulation of toxic metabolites including fumarylacetoacetate, maleylacetoacetate and succinylacetone (SA) presence in serum or urine is considered diagnostic for this condition.⁹ Diet restricted in tyrosine and phenylalanine has been used with partial response and liver transplantation has been the ultimate treatment for over 10 years.⁹ The introduction of NTBC, a compound that inhibits the enzyme 4-hydroxyphenylpyruvate deoxygenase and thereby prevents the accumulation of the presumed toxic metabolites has changed the course of the disease.¹⁰ Increasing clinical evidence has accumulated indicating that NTBC treatment reduces the need for liver transplantation, improves renal tubular function and if started early in the course of the disease (before 2 years of age) may decrease the risk for early development of hepatocellular carcinoma.^{10,32,33} Our patient had severe HTT1 with multiple complications involving liver and kidneys. Rapid clinical improvement was noted within the first few months of treatment with NTBC, and a diet restricted in tyrosine and phenylalanine. This was also accompanied by steady improvement in several laboratory parameters. We believe that this improvement is directly attributed to NTBC treatment.

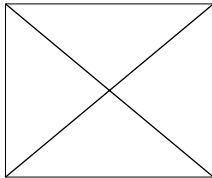
Finally, numerous cases of both conditions have been reported in the literature without reports of such association. To our knowledge, even non-specific craniofacial abnormalities are not reported with HTT1. One may hypothesize that HTT1 may activate any of the hypothesized pathogenetic mechanisms causing OAVS, however, such a hypothesis would be very difficult to perceive between such diverse conditions as HTT1 and OAVS.

References

- Goldenhar M. Associations malformatives de l'oeil et de l'oreille, in particulier le syndromic dermoide epibulbaire-appendices auriculaires-fistula auris congenita et ses relations avec la dysostose mandibulo-faciale. *J Genet Hum* 1952; 1: 243-282.
- Gorlin RJ, Cohen MM, Levin LS. Syndromes of the Head and Neck. New York (NY): Oxford University Press; 1990. p. 641-649, 707-708.
- Grabb WC. The first and second branchial arch syndrome. *Plast Reconstr Surg* 1965; 36: 485-508.
- Herrmann J, Opitz JM. A dominantly inherited first arch syndrome. *Birth Defects* 1960; 5: 110-112.
- Summitt RL. Familial Goldenhar syndrome. *Birth Defects* 1969; 5: 106-109.
- Cohen MM Jr. Variability versus "incidental findings" in the first and second branchial arch syndrome. Unilateral variants with anophthalmia. *Birth Defects* 1971; 7: 103-108.
- Regenbogen L, Godel V, Goya V, Goodman RM. Further evidence for an autosomal dominant form of oculoauriculovertebral dysplasia. *Clin Genet* 1982; 21: 161-167.
- Stoll C, Viville B, Treisser A, Gasser B. A family with dominant oculoauriculovertebral spectrum. *Am J Med Genet* 1998; 78: 345-349.
- Mitchell GA, Lambert M, Tanguay RM. Hypertyrosinemia. In: Scriver CR, Beaudet AL, Sly WS, Valle D, editors. The Metabolic and Molecular Bases of Inherited Disease. 7th ed. New York (NY): McGraw-Hill; 1995. p. 1077-1106.
- Lindstedt S, Holme E, Lock EA, Hjalmarson O, Strandvik B. Treatment of hereditary tyrosinaemia, type I by inhibition of 4-hydroxyphenylpyruvate dioxygenase. *Lancet* 1992; 340: 813-817.
- Kumar A, Friedman JM, Taylor GP, Patterson MWH. Pattern of cardiac malformation in oculoauriculovertebral spectrum. *Am J Med Genet* 1993; 46: 423-426.
- Rollnick BR, Kaye CI. Hemifacial microsomia and variants: pedigree data. *Am J Med Genet* 1983; 15: 233-253.
- Dyggve HV, Mikkelsen M. Partial deletion of the short arms of a chromosome of the 4-5 group (Denver). *Arch Dis Child* 1965; 40: 82-85.
- Ladexarl S. Combination of Goldenhar syndrome with the eridre-chat syndrome. *Acta Ophthalmol* 1968; 46: 605-610.
- Neu KW, Friedman JM, Howard-Peebles PN. Hemifacial microsomia in cri du chat (5p-) syndrome. *J Craniofac Genet Dev Biol* 1982; 2: 295-298.
- Greenberg F, Herman G, Stal S, Gruber H, Ledbetter DH. Chromosome abnormalities associated with facio-auriculo-vertebral dysplasia. Paper presented at the Clinical Genetics Conference, Minneapolis (MN): July 19-22, 1987.
- Poswillo D. The pathogenesis of the first and second branchial arch syndrome. *Oral Surgery* 1973; 35: 302-329.
- Poswillo D. Otomandibular deformity: pathogenesis as a guide to reconstruction. *J Maxillofac Surg* 1974; 2: 64-72.
- Poswillo D. Hemorrhage in development of the face. *Birth Defects Orig Artic Ser* 1975; 11: 61-81.
- Opitz JM. Blastogenesis and the "primary field" in human development. *Birth Defects* 1993; 29: 3-37.
- Kucera J. Rate and type of congenital anomalies among offspring of diabetic women. *J Reprod Med* 1971; 7: 61-70.
- Pederson LM, Tygstrup I, Pederson J. Congenital malformations in newborn infants of diabetic women. Correlation with maternal diabetic vascular complications. *Lancet* 1964; 1: 1124-1126.
- Becerra JE, Khoury MJ, Cordero JF, Erickson JD. Diabetes mellitus during pregnancy and the risks for specific birth defects: a population-based case-control study. *Pediatrics* 1990; 85: 1-9.
- Johnson JP, Carey JC, Gooch WM, Petersen J, Beattie JF. Femoral hypoplasia-unusual facies syndrome in infants of diabetic mothers. *J Pediatr* 1983; 102: 866-872.
- Ramos-Arroyo MA, Rodriguez-Pinilla E, Cordero JF. Maternal diabetes: the risk for specific birth defects. *Eur J Epidemiol* 1992; 8: 503-508.
- Berkenstadt M, Straussberg R, Goodman RM, Katznelson MBM, Goldman B, Barkai G. Concordance of auriculo-cardiovascular-skeletal malformations: a new malformation complex in an infant of a diabetic mother? *Am J Med Genet* 1991; 41: 26-29.

27. Johnson JP, Fineman RM. Branchial arch malformations in infants of diabetic mother: two case reports and a review. *Am J Med Genet* 1982; 13: 125-130.
28. Lin HJ, Owens TR, Sinow RM, Fu PC, DeVito A, Beall MH et al. Anomalous inferior and superior venae cavae with oculoauriculovertebral defect: review of Goldenhar complex and malformations of left-right asymmetry. *Am J Med Genet* 1998; 75: 88-94.
29. Grix A, Curry C, Hall BD. Patterns of multiple malformations, in infants of diabetic mothers. *Birth Defects Orig Artic Ser* 1982; 18: 55-77.
30. Ewart-Toland A, Yankowitz J, Winder A, Imagire R, Cox VA, Aylsworth AS et al. Oculoauriculovertebral abnormalities in children of diabetic mothers. *Am J Med Genet* 2000; 90: 303-309.
31. Pashayan H, Pinsky L, Fraser FC. Hemifacial microsomia-oculo-auriculo-vertebral dysplasia. A patient with overlapping features. *J Med Genet* 1970; 7: 185-188.
32. Kvittingen EA. Tyrosinaemia – treatment and outcome. *J Inherit Metab Dis* 1995; 18: 375-379.
33. Holme E, Lindstedt S. Tyrosinaemia type I and NTBC (2-nitro-4-trifluoromethylbenzoyl-1,3-cyclohexanedione). *J Inherit Metab Dis* 1998; 21: 507-517.

Related Abstract Source: Saudi MedBase



Saudi MedBase CD-ROM contains all medical literature published in all medical journals in the Kingdom of Saudi Arabia. This is an electronic format with a massive database file containing useful medical facts that can be used for reference. Saudi Medbase is a prime selection of abstracts that are useful in clinical practice and in writing papers for publication.

Search Word: goldenhar

Authors: Simon J. Krige
Institute: King Khaled Eye Specialist Hospital, Riyadh, Saudi Arabia
Title: Difficult intubation in a patient with Goldenhar's syndrome: a potential hazard of the use of the laryngeal mask airway (LMA)
Source: Saudi Journal of Ophthalmology 1996 April-June, 2: 85-87
Keywords: laryngeal mask airway, intubation

Abstract

A patient with Goldenhar's syndrome presented for elective oculoplastic surgery. After multiple failed attempts at tracheal intubation, a laryngeal mask airway (LMA) was inserted. The patient's respiration was controlled throughout the procedure. At the end of surgery a large blood clot from the traumatised larynx was found lodged behind the grille and inside the vestibule of the laryngeal mask airway. This report is presented to illustrate a potential problem in the use of the laryngeal mask airway following failed endotracheal intubation.