

# Traumatic fat embolism syndrome

Tarig S. Al-Khuwaitir, MRCP (UK), ABIM, Abdurahman M. Al-Moghairi, MBBS, Suphia M. Sherbeeni, MRCP (UK), MBBS, Hamed M. Subh, Facharzt for Orthopedics, MBBS.

---

## ABSTRACT

Traumatic fat embolism syndrome occurs most often following fractures of long bones sustained in road traffic accidents and is a common cause of medical consultation from the orthopedic surgery department. The sub-clinical presentation is subtle and expresses itself by the presence of hypoxemia, while the full clinical syndrome compromises respiratory insufficiency, an altered consciousness and a characteristic petechial rash. Recognition is simple once the patient is viewed in the context of his or her clinical setting. Diagnosis is aided further by the presence of hematological and biochemical abnormalities including anemia, thrombocytopenia, an elevated erythrocyte sedimentation rate and fat macroglobulinemia. Imaging by chest radiograph, computed tomography or magnetic resonance of the brain is used to confirm the extent of the respective organ involvement and to exclude alternative pathologies. The release of free fatty acids into the circulation and their subsequent effects is the key pathological event. Treatment is based on supportive care and high-dose corticosteroid therapy. We report a patient with traumatic fat embolism syndrome who developed the syndrome's classical symptoms and signs following fracture of the long bones of his left lower leg. Admission to an intensive care unit, mechanical ventilatory support with positive end-expiratory pressure and corticosteroid therapy lead to his improvement and allowed eventual open reduction and internal fixation and discharge of our patient. Modern therapy offers a relatively good prognosis for patients with traumatic fat embolism syndrome; the optimal dose and timing of corticosteroid therapy in prophylaxis and treatment however, remain the subject of intense debate.

Neurosciences 2003; Vol. 8 (1): 60-64

---

**D**isruption of the integrity of bone and the resultant release of its marrow defines the traumatic form of the fat embolism syndrome (FES).<sup>1</sup> The accurate overall incidence cannot be assessed as many sub-clinical forms remain unrecognized, however, the incidence of the clinically apparent syndrome is low, less than 1% in retrospective reviews.<sup>2,3</sup> The ability to produce frank respiratory failure, often enough to be a major cause of morbidity and mortality in patients with otherwise uncomplicated fractures, demonstrates the seriousness of FES.<sup>4</sup> In this report we present a patient with established FES, his diagnosis and management, as well as a discussion of the pathophysiological theories of this syndrome, according to the currently available evidence.

**Case Report.** A 23-year-old Saudi male sustained an injury to his left lower leg after being hit by an

automobile while crossing a busy intersection in downtown Riyadh and was admitted to the Orthopedic Department of Riyadh Medical Complex in July 2001. He had no past medical or surgical history of note and did not suffer from any allergies nor take any prescription or nonprescription medication. His initial physical examination revealed a left leg deformity with abnormal mobility of the extremity and when x-ray results confirmed a fracture of his left tibia and fibula he was booked for surgery. Heparin administration 5000 units subcutaneously 3 times a day was commenced. In the early morning hours of day 2, the patient started to complain of severe headache and paracetamol 1gm, one dose, was prescribed orally followed by a diclofenac 75 mg injection intramuscularly. However, the patient became irritable, restless and short of breath and was started on 5 liters per minute of oxygen (O<sub>2</sub>) by face-mask. During the orthopedic grand round later that

---

From the Department of Internal Medicine (Al-Khuwaitir, Al-Moghairi, Sherbeeni) and the Department of Orthopedic Surgery (Subh), Riyadh Medical Complex, Riyadh, Kingdom of Saudi Arabia.

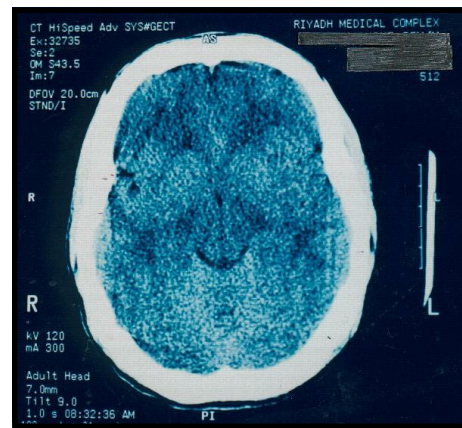Published simultaneously with special permission from Saudi Medical Journal.

Address correspondence and reprint request to: Dr. Tarig S. Al-Khuwaitir, Department of Internal Medicine, Riyadh Medical Complex, PO Box 3847, Riyadh 11481, Kingdom of Saudi Arabia. Tel/Fax. +966 (1) 4783446. E-mail: tarig\_alkhuwaitir@hotmail.com


day, he was found to be confused and a neurosurgical consultation obtained advised for a computerized tomography (CT) scan of the brain. In the evening, he became very agitated and had to be restrained. On day 3, the findings of the brain CT scan (**Figure 1**) revealed mild brain edema and the neurosurgeon ordered the administration of mannitol 20% 100 ml 3 times a day. The patient eventually developed severe shortness of breath while on O<sub>2</sub>, became febrile, a skin rash developed (**Figure 2**) and a medical consultation was called for.

Physical examination revealed a patient in acute respiratory distress with a respiratory rate of 30 breaths per minute, a temperature of 38.8°C, a blood pressure (BP) of 100/70 and a pulse rate of 100 per minute. A petechial rash was noted involving the neck and upper torso. Examination of the respiratory system revealed diffuse inspiratory coarse crepitations, the abdominal and cardiovascular examinations were unremarkable, the central nervous system examination revealed a disoriented and irritable patient with no focal neurological signs, no papilledema and no neck stiffness. Locomotor system examination revealed a plaster of Paris applied to the left lower limb. A bedside urinalysis was normal. Laboratory investigations showed an arterial blood gases result with a pH of 7.456, partial carbon dioxide (CO<sub>2</sub>) of 32 mm Hg, partial O<sub>2</sub> of 68.7 mm Hg, bicarbonate (HCO<sub>3</sub>) of 22.4 mm/L and saturation of 94.3% on 6 liters O<sub>2</sub> per minute via facemask. The full blood count showed a white cell count of  $12 \times 10^3/\text{mm}^3$  (16.1 on admission) with 78.6% neutrophils and a hemoglobin level of 13 g/dl (14.9 on admission) and a platelet count of 91 (204 on admission). Erythrocyte sedimentation rate (ESR) was 45 mm/first hour. Results of his blood glucose, urea and electrolytes were within normal range including calcium level. Results of a liver function test were normal, and a coagulation profile revealed normal parameters including D-dimer levels. A urine sample ordered for fat globules reported positive. Electrocardiogram findings showed right axis deviation and sinus tachycardia of 139 beats per minute. A chest radiograph revealed extensive bilateral interstitial infiltrates (**Figure 3**).

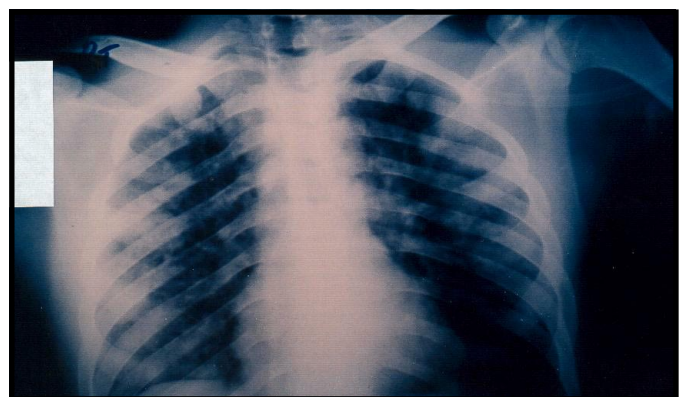The patient was admitted to the intensive care unit (ICU) with the diagnosis of fat embolism based on the presence of the characteristic history of a long bone fracture, the subsequently induced acute respiratory distress syndrome, the presence of cerebral dysfunction without head trauma, the typical petechial rash, pyrexia, thrombocytopenia and the finding of fat globules in his urine. He was intubated and ventilated with positive end-expiratory pressure (PEEP) adjusted to maintain saturation above 90%, his fluid administration regulated to maintain an optimal central venous pressure and urine output. Methylprednisolone 2 grams intravenously in 3 divided doses every 8 hours, each dose to be infused slowly over 15-30 minutes was given and unfractionated heparin continued subcutaneously as before. The next morning, on day 4 of his admission, the patient's



**Figure 1** - Computed tomography scan showing mild cerebral edema.



**Figure 2** - Petechial rash over lateral part of the trunk.



**Figure 3** - Chest radiography showing the "snow-storm" appearance of pulmonary edema in fat embolism syndrome.

temperature was 36.4°C, pulse was 128-145 beats per minute. Blood pressure was 127/53 mm Hg and his respiratory rate 16 per minute while ventilated, maintaining 96% O<sub>2</sub> saturation with a PEEP of 10 and fraction of inspired oxygen (FiO<sub>2</sub>) of 100%. He was sedated, and pupils were equal and reactive and examination of the chest revealed few bilateral inspiratory crackles. The rest of the physical exam was unremarkable. The chest radiograph revealed now a few areas of atelectasis in addition to the previously noted infiltrates. On day 5 of admission, the patient began to fight the ventilator once sedation was allowed to wear off but did not follow commands and he spiked a temperature of 38°C; a septic screen was carried out, C-reactive protein ordered and the patient's antibiotic therapy changed to ceftazidime one gram every 8 hours and amikacin 500 mg every 12 hours. On day 6, his pulse rate became 85 beats per minute, BP 125/53 mm Hg, temperature 38.2°C and respiratory rate 21 breaths per minute, findings of the chest radiograph revealed a fine mottling appearance predominantly involving the left lobe. On day 7 of admission, day 5 in the ICU, the patient became oriented and followed commands to the point. Examination of the chest revealed good air entry. The FiO<sub>2</sub> could be reduced to 40% and with no PEEP applied he maintained a saturation of 96%. Culture results of tracheal aspirate, blood and urine had been negative but C-reactive protein result was positive with a titer of 25.6 mg/dl and the present course of antibiotics continued. On day 8, the patient was weaned from the ventilator and extubated on day 9. On day 10, after 8 days in the ICU, the patient was transferred to the ward, afebrile, fully oriented with normal examination of his chest and the infiltrates on his chest radiograph had resolved. On day 19, he finally underwent open reduction and internal fixation of his fractures, and was discharged on day 33 in good health.

**Discussion.** Fat embolism syndrome occurs when neutral fat (NF) is released into the circulation leading to fat macroglobulinemia and its clinical manifestations.<sup>5</sup> This NF can arise from different sources and hence FES is divided into a traumatic form, which occurs usually after long bone fractures, intramedullary nailing or cemented and noncemented arthroplasty and a nontraumatic form resulting from corticosteroid therapy, administration of lipid emulsion infusions, as a rare complication of sickle cell disease, osteomyelitis, frostbite, acute pancreatitis, diabetes mellitus, burns, liposuction, cardiopulmonary bypass, decompression sickness and in subjects with fatty liver.<sup>2,6,7</sup> The 2 main hypotheses put forward to explain the pathophysiology of FES comprise the mechanical and the biochemical hypotheses.<sup>2</sup> In the former, fat corpuscles enter the cardiovascular circulation during peak intramedullary pressure being pressed out of broken bone into the capillaries leading to mechanical obstruction of pulmonary arteries; these fat emboli can deform and traverse the lungs resulting in systemic embolization,

most commonly to the brain and kidneys.<sup>2,8</sup> A patent foramen ovale constitutes an alternative route of entering the systemic circulation and has been reported to result in FES without pulmonary involvement.<sup>3</sup> The source of these emboli has been traced to the injured extremity.<sup>3</sup>

In the biochemical hypotheses of traumatic FES, several distinct processes are taking place in which bone marrow fat (a tremendous stimulus for activation of the clotting system), platelet activation and a subsequent systemic inflammatory response of the lungs triggers the release of local mediators, causing damage to pulmonary membranes leading to disturbed gas exchange and respiratory insufficiency.<sup>1</sup> C-reactive protein, which rises tremendously in cases of trauma, causes calcium-dependent agglutination of liposomes, chylomicrons and very low density lipoproteins, and is thought to take center stage in the formation of emboli in FES.<sup>9</sup> The increased release of catecholamines after major injury and the subsequently induced lipolysis increases the levels of free fatty acids (FA).<sup>6</sup> Neutral fats, known also as triglycerides, are thought to be liberated by the actions of lipases which are increased after trauma.<sup>3</sup> Plasma FA increase lipid peroxidation with potential severe oxidative stress to the lungs.<sup>2</sup>

Fat embolism (FE) has been known for over a century and was originally described by Zenker<sup>10</sup> in 1882, yet diagnosis needs a high index of suspicion in the absence of overt FES as the incidence of clinically apparent FES has been reported in only 1-5% of fracture patients.<sup>11,12</sup> Hence, FES can occur in sub-clinical and clinical forms where the sub-clinical form is diagnosed using criteria proposed by Lindeque et al which includes: a partial O<sub>2</sub> value of <60 mm Hg, a partial CO<sub>2</sub> of >55 mm Hg, pH <7.3, a respiratory rate of >35 breaths per minute and increased work of breathing.<sup>13</sup> Any patient exhibiting one or more of these criteria in the presence of a fracture of the femur, tibia, or both, was diagnosed with FES.<sup>13</sup>

The clinical manifestations of FES described by Gurd<sup>14</sup> in 1970, and refined by Gurd and Wilson<sup>15</sup> in 1974 are classically expressed in our patient. They occur after a symptom free interval of 6-12 hours and comprise the aforementioned major criteria of respiratory, cerebral and dermatological involvement and minor criteria comprising pyrexia, tachycardia, retinal and renal changes, jaundice, anemia, thrombocytopenia, a high ESR and fat macroglobulinemia.<sup>15</sup> At least 2 major criteria or one major and 4 minor criteria have to be present in order to diagnose the syndrome according to Gurd and Wilson.<sup>15</sup> Following fracture of his left tibia and fibula our patient developed FES after a lag period of 9 hours, in a classical sense exhibiting all 3 of Gurd's major criteria within 48 hours of his trauma. This full syndrome develops usually within 12-72 hours following the symptom-free interval.<sup>12,13</sup>

The neurological manifestations are usually in the form of a diffuse encephalopathy as demonstrated in our patient, other diagnoses have to be entertained if focal cerebral syndromes develop.<sup>12</sup> Although the confusional state of the patient could be attributed to the hypoxia

secondary to the development of respiratory distress syndrome, severe cerebral involvement without pulmonary involvement has been described in patients with FES.<sup>6</sup> The nonpalpable petechiae occur mainly in the axillae, on the trunk (**Figure 2**), neck, subconjunctival and mucous membranes of the mouth and are regarded as a delayed result of disseminated intravascular coagulation and often are the last manifestation to appear.<sup>2</sup> Examined under the light microscope, the petechiae are composed of small droplets of fat that are obstructing capillaries and are surrounded by small perivascular hemorrhages.<sup>6</sup>

The diagnosis of FES is supported by the finding of urinary fat globules stained with Sudan III and IV.<sup>15</sup> Estimation of fat macroglobulinemia, although demonstrated to occur in traumatic FE by Gurd and Wilson,<sup>15</sup> has not found its way into the diagnostic work-up as yet. The staining of macrophages for fat droplets in bronchoalveolar lavage specimens is of diagnostic value and their quantification increases the diagnostic sensitivity and specificity with a threshold value of greater than 30% stain-positive macrophages.<sup>2,16</sup> Blood investigations reveal thrombocytopenia, unexplained anemia, hypocalcemia due to free FA affinity to calcium and hypoalbuminemia.<sup>15</sup> A 'snow storm appearance' is classical with multiple bilateral patchy areas of consolidation in the middle and upper zones (**Figure 3**).<sup>3</sup> Although magnetic resonance imaging of cerebral FE is the better diagnostic tool for detecting brain embolism than CT of the brain, the former needs a technical setting able to accommodate patients on mechanical ventilation.<sup>2,17</sup> Other diagnostic methods include the use of single photon emission CT and transcranial Doppler sonography. Studies comparing all 4 modalities of intracranial imaging in FES are to our knowledge not yet available.<sup>18</sup>

The prevention of traumatic FES could have been accomplished by a rigorous policy of early operative intervention in long bone fractures of our patient, and those alike, usually within 24 hours of admission.<sup>8</sup> If this is not possible due to traumatic shock, then measures to restore the normal microcirculation, replacement of blood losses, the control of hypoxia by mechanical ventilation if necessary and the maintenance of a high caloric intake to prevent excessive lipolysis should be implemented.<sup>19</sup> The replacement of fluid loss by human albumin is preferred due to its ability to bind free FA.<sup>11</sup>

Acetyl salicylic acid prevents abnormalities in gas exchange and reduces platelet adhesiveness, and its administration is recommended.<sup>20</sup> "Low-dose" corticosteroid therapy in a dose of 9 mg/kg methylprednisolone, in a study by Kallenbach et al,<sup>20</sup> provided protection against FES after skeletal trauma where fat embolism occurred in 10 controls (23.8% of 42 patients) and one steroid-treated patient (2.5% of 40 patients) ( $p=0.01$ ) a significant difference, fulminant infection however is a potentially fatal side effect and this practice needs further evaluation.<sup>21</sup>

Once the FES is established, and as in the case presented leads to increasing respiratory distress despite supplemental oxygen, mechanical ventilation with PEEP is usually necessary to maintain adequate oxygenation.<sup>13</sup>

Despite 140 years since its first description, the treatment of established FES by pharmacological means remains an area of controversy with different therapeutic modalities purported at different times and available treatment recommendations spanning over 3 decades. The fact that patients with elevated blood alcohol levels and femoral fractures had a lower incidence of FES lead to a renewed interest in alcohols ability to decrease serum lipase activity and thereby to decrease the production of free FA, however, no recommendation to its use can be found in present literature presumably due to the absence of an inverse relationship between alcohol levels and those of free FA and protection from FES.<sup>11</sup> Heparin interferes with lipid metabolism by a "creaming phenomenon" clearing lipemic serum by stimulating lipase activity; reports on its effectiveness are conflicting and its use in multiple trauma patients may potentially cause serious bleeding, hence, its use cannot be recommended in the former setting, however it may have a role in cases less threatened by bleeding and is still recommended in handbooks of acute medicine.<sup>2</sup> Dextran 40 is not recommended by any reference encountered in the current literature due to its many side effects.<sup>3,11</sup> Corticosteroids usually in the form of methylprednisolone, given once or thrice often in divided doses ranging between 9-90mg/kg have been studied in prevention and treatment of FES with impressive results.<sup>13,20</sup> They limit the rise of free FA, stabilize membranes and inhibit complement-mediated leukocyte aggregation.<sup>11</sup> The optimum timing of administration and its rationale however is not as yet established, neither is the optimal dose. The prognosis of FES is generally good, with the aforementioned adequate modern supportive care and without associated life-threatening diseases.<sup>22</sup>

Our patient improved on a dose of 30 mg/kg methylprednisolone administered for one day in 3 divided doses based on Lindeque et al.<sup>13</sup> Whether his improvement was due to its administration or to the supportive care alone cannot be ascertained. In 1997 ten Duis<sup>6</sup> doubted the justification of using the concept of FES, suggesting fat embolism to be an epiphenomenon that accompanies any patient with skeletal injuries. Following our review of the literature in preparing this case report, we tend to concur with his view. We would like to re-emphasize that future attempts to unravel this syndrome, as mentioned by ten Duis,<sup>6</sup> should focus on differences in the extent of accompanying soft-tissue injuries that surround a long bone fracture and the reaction it produces and not only on the breakdown pathways of triglycerides, in view of the many different proteins involved in the acute phase reaction following an injury. However, we hope that our case will add to the available clinical acumen and will provide an impetus for future research in the fine-tuning of treatment for this condition.

## References

1. Shier MR, Wilson RF. Fat embolism syndrome: traumatic coagulopathy with respiratory distress. *Surg Annu* 1980; 12: 139-168.
2. Estebe JP. From fat emboli to fat embolism syndrome. *Ann Fr Anesth Reanim* 1997; 16: 138-151.
3. Mellor A, Soni N. Fat embolism. *Anaesthesia* 2001; 56: 145-154.
4. Schonfeld SA, Ploysongsang Y, Di Lisio R, Crissman JD, Miller E, Hammerschmidt DE et al. Fat embolism prophylaxis with corticosteroids. A prospective study in high risk patients. *Ann Intern Med* 1983; 99: 438-443.
5. Coosling H, Pelligrini V. Fat embolism syndrome. *Clin Orthop* 1982; 165: 68-92.
6. ten Duis HJ. The fat embolism syndrome. *Injury* 1997; 28: 77-85.
7. Urano T, Tajiri S. Fat embolism syndrome. *Ryoikibetsu Shokogun Shirizu* 2000; 30: 396-399.
8. Richards RR. Fat embolism syndrome. *Can J Surg* 1997; 40: 334-339.
9. Hulman G. The pathogenesis of fat embolism. *J Pathol* 1995; 176: 3-9.
10. Zenker FA. Beitrage zur normalen und pathologischen Anatomie der Lungen. Dresden (DE): J Branunsdorf; 1862. p. 31.
11. Van Besouw JP, Hinds CJ. Fat embolism syndrome. *Br J Hosp Med* 1989; 42: 304-311.
12. Jacobsen DM, Terrence CF, Reinmuth OM. The neurologic manifestations of fat embolism. *Neurology* 1986; 36: 847-851.
13. Lindeque BGP, Schoeman HS, Dommisse GF, Boeyens MC, Vlok AL. Fat embolism and the fat embolism syndrome: A double-blind therapeutic study. *J Bone Joint Surg Br* 1987; 68: 128-131.
14. Gurd AR. Fat embolism: An aid to diagnosis. *J Bone Joint Surg Br* 1970; 52: 732-737.
15. Gurd AR, Wilson RI. The fat embolism syndrome. *J Bone Joint Surg Br* 1974; 56-B: 408-416.
16. Godeau B, Schaeffer A, Bachir D, Fleury-Feith J, Galacteros F, Verra F et al. Bronchoalveolar lavage in adult sickle cell patients with acute chest syndrome: value of diagnostic assessment of fat embolism. *Am J Resp Crit Care Med* 1996; 153: 1691-1696.
17. Chrysikopoulos H, Maniatis V, Pappas J, Filalithis P, Gogali C, Sfyras D. Case report: post-traumatic cerebral fat embolism: CT and MR findings. Report of two cases and review of the literature. *Clin Radiol* 1996; 51: 728-732.
18. Prentiss JE, Imoto EM. Fat embolism, ARDS, coma, death: the four horsemen of the fractured hip. *Hawaii Med J* 2001; 60: 15-19.
19. Kroupa J. The role of pharmacology in the comprehensive prophylaxis of post-traumatic fat embolism. *Acta Chir Orthop Traumatol Cech* 1993; 60: 114-122.
20. Shier MR, Wilson RF, James RE, Riddle J, Mammen EF, Pedersen HE. Fat embolism prophylaxis: a study of four treatment modalities. *J Trauma* 1977; 17: 621-629.
21. Kallenbach J, Lewis M, Zaltzman M, Feldman C, Orford A, Zwi S. Low dose corticosteroid prophylaxis against fat embolism. *J Trauma* 1987; 27: 1173-1176.
22. Guenter CA, Braun TE. Fat embolism syndrome. Changing prognosis. *Chest* 1981; 79: 143-145.