

Study of the anatomical variations of the musculocutaneous nerve

Mohammed H. Badawoud, MBBCh, PhD.

ABSTRACT

Objectives: To study the anatomical variations of the musculocutaneous nerve.

Methods: Fifty-four arms from embalmed adult cadavers were utilized for this investigation. They were carefully dissected and examined for any anatomical variations of the musculocutaneous nerve. This study was performed at the Department of Anatomy, King Abdul-Aziz University, Jeddah, Kingdom of Saudi Arabia between 2001 and 2003.

Results: Four anomalies of the musculocutaneous nerve were found in this study. One case showed that the musculocutaneous nerve pierced the coracobrachialis muscle and passed inside the muscle for some distance. The nerve pierced the coracobrachialis muscle again, and it ran

downward and medially and joined the median nerve at the middle of the arm. The brachial artery was sandwiched between the musculocutaneous and the median nerves. Three cases demonstrated that the musculocutaneous nerve did not pierce the coracobrachialis muscle and passed downward and medial to it. The nerve joined the median nerve at the junction of the upper third with the lower two-thirds of the arm. The musculocutaneous nerve was completely absent in one case. In another case, the musculocutaneous nerve originated from the upper part of the median nerve.

Conclusion: The knowledge of the anatomical variations of the musculocutaneous nerve may have clinical and surgical implications.

Neurosciences 2003; Vol. 8 (4): 218-221

The musculocutaneous nerve usually originates from the lateral cord of the brachial plexus, pierces and supplies the coracobrachialis muscle. The nerve runs obliquely downward between the biceps brachii and brachialis muscles and supplies them. It ends by piercing the deep fascia lateral to the tendon of the biceps brachii muscle and continues in the forearm as the lateral cutaneous nerve of the forearm.¹ However, variations in the course and branching of the musculocutaneous nerve have been mentioned in the literature. The musculocutaneous nerve may not pierce the coracobrachialis muscle and become adherent to the median nerve.²⁻⁴ The musculocutaneous nerve could arise from the median nerve or the posterior cord of the brachial plexus.⁵ Interconnecting branches were found between the musculocutaneous and the median nerves.^{6,7}

The musculocutaneous nerve may be totally absent.^{2,8-10} In this study the musculocutaneous nerve in 54 arms was examined in our laboratory and the variations were reported. The results of this study showed variations in the origin and course of musculocutaneous nerve, which may have clinical and surgical implications.

Methods. The embalmed adult cadavers used in our laboratory were examined in this study. Fifty-four arms were used in this investigation. They were obtained from 27 adult cadavers. They were examined for any anatomical variations of musculocutaneous nerve. The cadavers used in this study do not have the same racial origin. This study was performed at the Department of Anatomy, King Abdul-Aziz University, Jeddah, Kingdom of Saudi Arabia between 2001 and 2003.

From the Department of Anatomy, Faculty of Medicine and Allied Sciences, King Abdul-Aziz University, Jeddah, Kingdom of Saudi Arabia.

Received 6th April 2003. Accepted for publication in final form 4th May 2003.

Address correspondence and reprint request to: Dr. Mohammed H. Badawoud, Assistant Professor, Department of Anatomy, Faculty of Medicine and Allied Sciences, King Abdul-Aziz University, Jeddah, Kingdom of Saudi Arabia. Tel. +966 (2) 6403443 Ext. 20049. Fax. +966 (2) 6551144. E-mail: mbadawoud@hotmail.com

Results. **Anomaly one (Figure 1).** The musculocutaneous nerve originated from the lateral cord of the brachial plexus and pierced the coracobrachialis muscle as usual. It descended in the substance of the muscle for some distance and then the nerve pierced the muscle again. The musculocutaneous nerve was superficial and passed downward and medially to join the median nerve in the middle of the arm. The musculocutaneous nerve gave branches to supply the brachialis and biceps brachii muscles before it joined the median nerve. The brachial artery was sandwiched between the musculocutaneous and the median nerves. This anomaly was unilateral in the right arm of one cadaver (1.9%).

Anomaly 2 (Figure 2). The musculocutaneous nerve did not pierce the coracobrachialis muscle and descended downward and medial to it. The musculocutaneous nerve joined the median nerve at the junction of the upper third with the lower two-thirds of the arm. The nerve gave branches to supply the coracobrachialis, brachialis and biceps brachii muscles. This anomaly was present in 3 cases (5.6%). It was unilateral in the right arms of 2 cadavers and in the left arm of one cadaver.

Anomaly 3 (Figure 3). The musculocutaneous nerve was absent and the coracobrachialis, brachialis and biceps brachii muscles received their nerve supply from the lateral root of the median nerve. This anomaly was unilateral in the right arm of one cadaver (1.9%).

Anomaly 4 (Figure 4). The musculocutaneous nerve originated from the upper part of the median nerve. It ran laterally in a horizontal course and pierced the coracobrachialis muscle. The right arm of one cadaver showed this anomaly and it was unilateral (1.9%).

Forty-eight arms showed the usual origin and course of the musculocutaneous nerve (**Figure 5**). The nerve originated from the lateral cord of the brachial plexus and pierced the coracobrachialis muscle (88.9%).

Discussion. As the musculocutaneous nerve pierces the coracobrachialis muscle, it may be predisposed to compression and injury by vigorous muscular exercise or chronic compression caused by hypertrophy of the coracobrachialis muscle.^{11,12} The musculocutaneous nerve usually pierces the coracobrachialis muscle and descends between the biceps brachii and brachialis muscles.¹ Thus, the musculocutaneous nerve is protected by these muscles and isolated nerve injury is not common, however, cases of isolated nerve injury were reported in the literature.¹¹⁻¹⁵ In anomaly one (**Figure 1**), the musculocutaneous nerve left the coracobrachialis muscle and passed downward and medially in a superficial course before it joined the median nerve. This superficial course makes the nerve more susceptible to injury by trauma to the arm or during surgical operations in this area. In this anomaly, the musculocutaneous nerve pierced the coracobrachialis muscle, ran for some distance inside the muscle and then pierced the muscle again. This course inside

coracobrachialis muscle makes the nerve more predisposed to isolated nerve injury due to compression by the muscle. The musculocutaneous nerve runs inside the hypertrophied coracobrachialis muscle for a longer distance than normal and it becomes more predisposed to compression by the hypertrophied coracobrachialis muscle in athletes.^{11,12} This could support our suggestion.

The musculocutaneous, median, and ulnar nerves originate from a common nerve mass. This nerve mass divides into common median and musculocutaneous nerve trunk and ulnar nerve and then the common median and musculocutaneous nerve trunk divides into median and musculocutaneous nerves. The incomplete division of this trunk may lead to incomplete separation of the median and musculocutaneous nerves and failure of the musculocutaneous nerve to pierce the coracobrachialis muscle.³ This may explain the communication between the lower part of the musculocutaneous nerve and the median nerve found in anomaly one (**Figure 1**). This may also explain anomaly 2 (**Figure 2**), where the musculocutaneous nerve did not pierce the coracobrachialis muscle and its lower part was connected to the median nerve. A connection between the musculocutaneous and median nerves was reported. An interconnecting branch originated from the musculocutaneous nerve at the level of the lateral border of the coracobrachialis and joined the median nerve.¹⁶ Adhesion between the median and musculocutaneous nerves has been reported before. Cases, where the musculocutaneous nerve did not pierce the coracobrachialis muscle and was adherent to the median nerve were reported in the literature.^{2,3} A case, where the musculocutaneous nerve ended by joining the median nerve was also reported.⁴ Different patterns of connection between the musculocutaneous and the median nerves were reported.⁶ Adhesion and a connecting branch between the 2 nerves were also found.⁶

Anomaly one (**Figure 1**) also demonstrated that the brachial artery was sandwiched between the median and musculocutaneous nerves. This may lead to compression of the artery by these nerves and impair its blood flow. An interconnecting branch between the musculocutaneous and median nerves was reported. It was also reported that the close relation of this interconnecting nerve to the brachial artery could result in compression of the artery and impair the blood supply to the upper limb.⁷ A case of brachial artery compression due to muscular hypertrophy was described.¹⁷ The brachial artery may be compressed by the supracondylar process.^{18,19} Cases, where the brachial artery was compressed by lacertus fibrosus (bicipital aponeurosis) were reported.²⁰ All the cases were athletes with hypertrophied forearm muscles. According to the finding of the literature review, anomaly one, found in this study, seems to be the first reported case.

In anomaly 2 (**Figure 2**), the musculocutaneous nerve did not pierce the coracobrachialis muscle and the risk of developing compression injury of the nerve will be

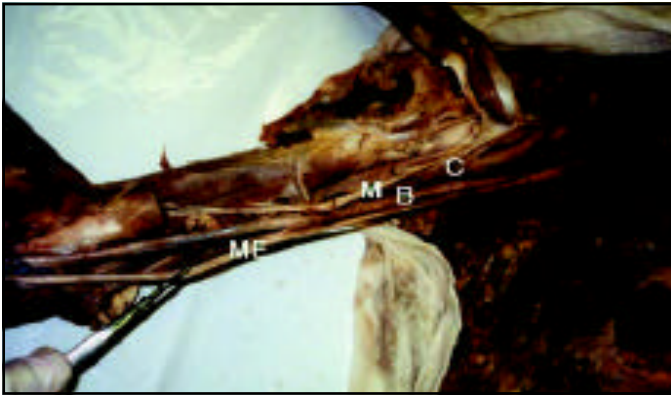


Figure 1

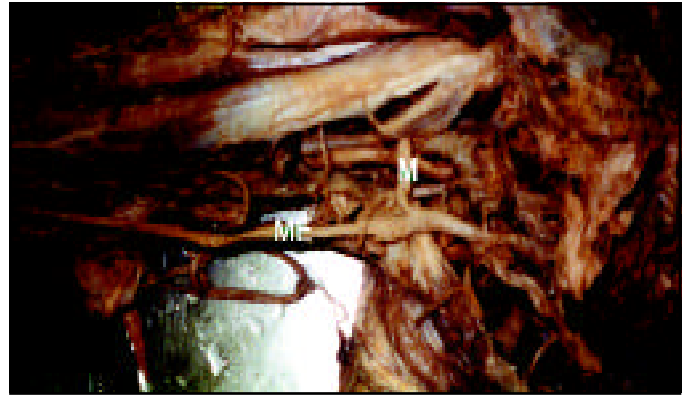

Figure 4

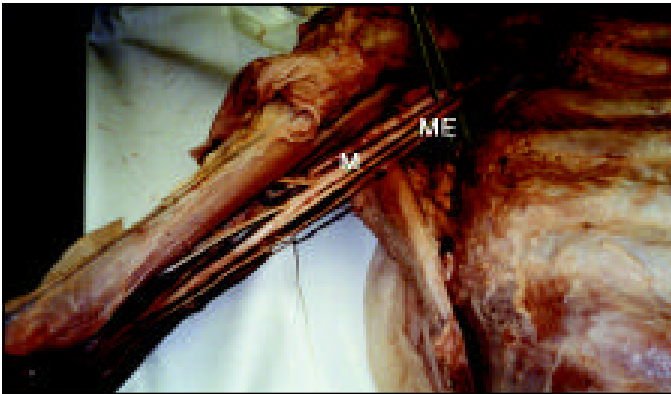


Figure 2

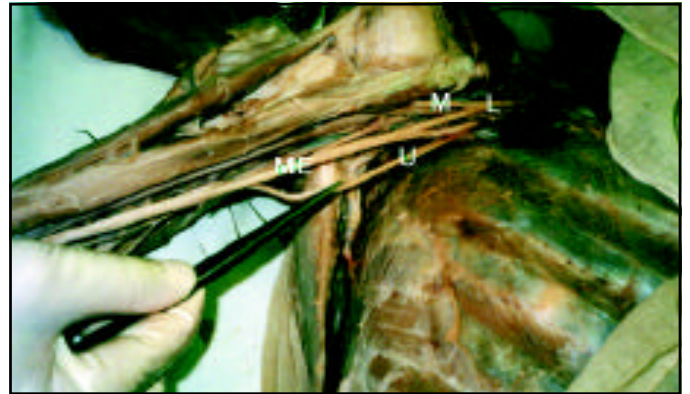


Figure 5



Figure 3

Figure 1 - A photograph of the right arm of an adult cadaver, showing the musculocutaneous nerve (M), which pierces coracobrachialis muscle (C) and passes downward for some distance inside the muscle before it pierces the muscle again. The musculocutaneous nerve joins the median nerve (ME). The brachial artery (B) is sandwiched between the musculocutaneous and the median nerves. Note that, the musculocutaneous nerve gives branches to supply brachialis and biceps muscles before it joins the median nerve.

Figure 2 - A photograph of the right arm of an adult cadaver, showing the musculocutaneous nerve (M). Note that, the nerve does not pierce coracobrachialis muscle and it joins the median nerve (ME) at the junction of the upper third with the lower two-thirds of the arm.

Figure 3 - A photograph of the right arm of an adult cadaver. The musculocutaneous nerve is absent. The muscles of the anterior compartment of the arm are supplied by branches, which arise from the lateral root (L) of the median nerve (ME).

Figure 4 - A photograph of the right arm of an adult cadaver. The musculocutaneous nerve (M) arises from the upper part of the median nerve (ME).

Figure 5 - A photograph of the right arm of an adult cadaver, showing the normal origin and course of the musculocutaneous nerve (M). The nerve originates from the lateral cord (L) of the brachial plexus. ME - median nerve, U - ulnar nerve.

absent. The nerve also had a superficial course in the upper part of the arm and subsequently it will be predisposed to injury by trauma or surgical procedures in this area. A similar case, where the musculocutaneous nerve did not pierce the coracobrachialis muscle and passed downward and medial to it was reported.⁵

In anomaly 3 (**Figure 3**) found in this study, the musculocutaneous nerve was absent and the branches to biceps brachii, brachialis and coracobrachialis muscles originated from the lateral root of the median nerve. This finding may be caused by complete failure of the division of the median nerve and musculocutaneous nerve common trunk as mentioned before. Similar cases, where the musculocutaneous nerve was completely absent were found.^{2,8-10} A case, where the median nerve, musculocutaneous nerve and the lateral cord of brachial plexus were present in a common connective tissue sheath was reported.³ In other reports, communicating branches were present between the median and musculocutaneous nerves.^{21,22}

In anomaly 4 (**Figure 4**), the musculocutaneous nerve originated from the upper part of the median nerve and pierced the coracobrachialis muscle. It was reported that the musculocutaneous nerve might originate from the median nerve or the posterior cord of the brachial plexus.⁵

This study has reported a number of anatomical variations of the musculocutaneous nerve. The knowledge of these anatomical variations is important as it may help in the diagnosis and treatment of compression or traumatic injury of the musculocutaneous nerve.

Acknowledgment. The author would like to thank Professor Mohammed Salah and Professor Mostafa El-Naggar for their help during this study.

References

- Williams PL, Warwick R, Dyson M, Bannister LH. Neurology. In: Gray's anatomy. Edinburgh (UK): Churchill Livingstone; 1989. p. 1132.
- Koizumi M. A morphological study on coracobrachialis muscle. *Acta Anat Nippon* 1989; 64: 18-35.
- Nakatani T, Mizukami S, Tanaka S. Three cases of musculocutaneous nerve not perforating the coracobrachialis muscle. *Acta Anat Nippon* 1997; 72: 191-194.
- El-Nagar M. A study on the morphology of the coracobrachialis muscle and its relationship with the musculocutaneous nerve. *Folia Morphol* 2001; 60: 85-90.
- Gumusalan Y, Yazar F, Ozan H. Variant innervation of the coracobrachialis muscle and unusual course of the musculocutaneous nerve in man. *Acta Anat Nippon* 1998; 73: 269-272.
- Choi D, Rodriguez-Niedenfuhr M, Vazquez T, Parkin I, Sanudo JR. Patterns of connections between the musculocutaneous and median nerves in the axilla and arm. *Clin Anat* 2002; 15: 11-17.
- Sargon MF, Uslu SS, Celik HH, Aksit D. A variation of the median nerve at the level of brachial plexus. *Bull Assoc Anat* 1995; 79: 25-26.
- Golan J, Kaus M, Szwarc P. High origin of the ulnar and radial arteries in human. *Folia Morphol* 1994; 53: 37-43.
- Nakatani T, Tanaka S. Absence of the musculocutaneous nerve with innervation of coracobrachialis, biceps brachii, brachialis and the lateral border of the forearm by branches from the lateral cord of the brachial plexus. *J Anat* 1997; 191: 459-460.
- Gumusburun E, Adiguzel E. A variation of the brachial plexus characterized by the absence of the musculocutaneous nerve: a case report. *Surg Radiol Anat* 2000; 22: 63-65.
- Braddom R, Wolfe C. Musculocutaneous nerve injury after heavy exercise. *Arch Phys Med Rehabil* 1978; 59: 290-293.
- Pecina M, Bojanic I. Musculocutaneous nerve entrapment in the upper arm. *Int Orthop* 1993; 17: 232-234.
- Kim S, Goodrich A. Isolated proximal musculocutaneous nerve palsy: case report. *Arch Phys Med Rehabil* 1984; 65: 735-736.
- Mastaglia F. Musculocutaneous neuropathy after strenuous physical activity. *Med J Aust* 1986; 145: 153-154.
- Cisneros C, Geiringer S. Isolated musculocutaneous nerve injury: A case report. *Int J Occup Environ Health* 1995; 1: 257-259.
- Uzun A, Leonard L, Seelig J. A variation in the formation of the median nerve: communicating branch between the musculocutaneous and the median nerve in man. *Folia Morphol* 2001; 60: 99-101.
- Biemans R. Brachial artery entrapment syndrome. Intermittent arterial compression as a result of muscular hypertrophy. *J Cardiovasc Surg (Torino)* 1977; 18: 367-371.
- Talha H, Enon B, Chevalier J, L'Hoste P, Pillet J. Brachial artery entrapment: compression by the supracondylar process. *Ann Vasc Surg* 1987; 1: 479-482.
- Bilge T, Yalaman O, Bilge S, Cokneseli B, Barut S. Entrapment neuropathy of the median nerve at the level of the ligament of Struthers. *Neurosurgery* 1990; 27: 787-789.
- Bassett Fr, Spinner R, Schroeter T. Brachial artery compression by the lacertus fibrosus. *Clin Orthop* 1994; 307: 110-116.
- Kosugi K, Shibata S, Yamashita H. Supernumerary head of biceps brachii and branching pattern of the musculocutaneous nerve in Japanese. *Surg Radiol Anat* 1992; 14: 175-185.
- Venieratos D, Anagnostopoulou S. Classification of communications between the musculocutaneous and median nerves. *Clin Anat* 1998; 11: 377-381.