

# Spontaneous bladder rupture in a non-augmented neuropathic bladder

Khalid F. Neel, MBBS, FRCSI.

---

## ABSTRACT

A spontaneous bladder rupture in an intact bladder without history of trauma has been reported before with different postulation for the pathogenesis. All these cases were reported in the adult age group. Patients with a neuropathic bladder associated with such a complication were post augmentation cystoplasty or catheter induced injury. We present our experience in a boy with a neuropathic bladder secondary to *spina bifida* who had a spontaneous bladder rupture with no surgical intervention carried out before, and discuss the possible pathogenesis.

Neurosciences 2004; Vol. 9 (2): 119-120

---

Patients born with *spina bifida* are well known to develop neuropathic bladder secondary to abnormal vesical innervations. They are in need of life long follow-up to abort damage to the urinary tract and prevent secondary complication early on.<sup>1</sup> Spontaneous perforation of the urinary bladder without history of trauma, surgery or spinal cord pathology has been earlier described.<sup>2-4</sup> Most of which are in the adult age group, either related to alcohol ingestion or other predisposing risk factors.<sup>4</sup> Spontaneous perforation of an augmented bladder is being reported with increasing frequency, where the common denominator seems to be impaired sensation in patients with *spina bifida*.<sup>5-7</sup> Bauer et al<sup>5</sup> postulated that the manner in which the bowel is reconfigured may lead to areas of relative or true ischemia. Others have theorized that when uninhibited contractions occur in the augmented bladder, the high pressure generated may contribute to a period of ischemia.<sup>8,9</sup>

In this study, we review our experience in a boy with *spina bifida* who presented with vesicocolic fistula secondary to spontaneous non-augmented urinary bladder perforation.

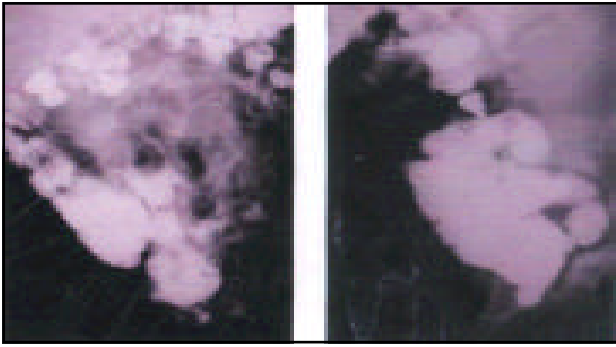
**Case Report.** We report a 12-year-old boy, known case of myelomeningocele, where repair was carried out as a neonate in another center. On post repair, the patient did not receive proper urological follow-up, and was never started on a clean intermittent catheterization program, and he was lost for follow-up for a long time in the referral center. He presented to the general pediatric clinic in our center due to the passage of “watery stool” for few days. The parents denied any history of trauma, and they claimed that he was always constipated before. Previous radiological examinations carried out in his early life showed mild bilateral hydronephrosis and a classical “christmas tree” neurogenic bladder. Upon this admission a urinary tract ultrasound showed severe bilateral hydroureteronephrosis with bladder trabeculation. A voiding cystourethrogram (**Figure 1**) showed a vesicocolic fistula without peritoneal spillage. His renal profile at this stage was normal, although the parents were told before that the child has mild renal impairment, which can be explained by the vesicocolic fistula working as a pop off mechanism, which protected his kidney

---

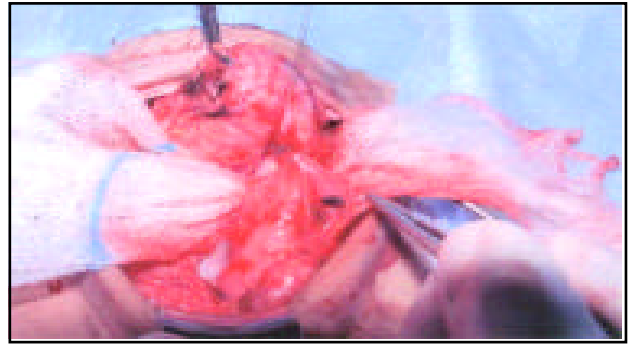
From the Department of Surgery, Division of Urology, College of Medicine, King Khalid University Hospital, King Saud University, Riyadh, Kingdom of Saudi Arabia.

Published simultaneously with special permission of Saudi Medical Journal.

Address correspondence and reprint request to: Dr. Khalid F. Neel, Assistant Professor and Consultant Pediatric Urologist, Department of Surgery, Division of Urology, College of Medicine, King Khalid University Hospital, King Saud University, PO Box 7805, Riyadh 11472, Kingdom of Saudi Arabia. Tel. +966 (1) 4672561. Fax. +966 (1) 4679493. E-mail. kfouada@ksu.edu.sa



**Figure 1** - Voiding cystourethrogram showing severe bladder trabeculation and a vesicocolic fistula.



**Figure 2** - Intraoperative picture showing area of the vesicocolic fistula between the sigmoid colon, and the posterior bladder wall near a small bladder saccule.

from further deterioration by providing drainage into low-pressure reservoir. The patient was admitted and had a laparotomy where the vesicocolic fistula was identified between the posterior wall of the bladder near a small bladder saccule and the sigmoid colon (**Figure 2**). The fistula was excised and bilateral end ureterostomy was carried out. We decided to follow-up the patient with his ureterostomy, considering his social and family background, until he is older. At which, time definitive management will be instituted.

**Discussion.** Although, spontaneous bladder rupture is being described in patients with augmented neuropathic bladders with increasing frequency,<sup>5-9</sup> such a phenomenon was only reported in few case reports with intact bladders without spinal cord pathology.<sup>2,4</sup> Maguire et al<sup>10</sup> deserves credit for the elaboration of what he described as the “at risk” bladder. They noted that if the bladder storage characteristics were such that urine leaked from the urethra when the intravesical pressure was greater than 40cm H<sub>2</sub>O, 81% of the patients manifested with hydronephrosis. The “at risk” bladder can further lead to renal impairment and end stage renal disease. The complication related to the high intravesical pressure can be aggravated by detrusor sphincter dyssynergia (DSD).<sup>1</sup> These studies pioneered the concept of the predictive value of urodynamic testing and led to the belief currently held by most investigators that storage of urine at pressures above 40cm H<sub>2</sub>O or the presence of DSD is potentially harmful to the upper urinary tract. Accordingly, the proactive management of neurogenic bladders secondary to *spina bifida* is well established in most centers.<sup>1</sup> Most of the previous reports<sup>5-9</sup> postulate the reason for perforation in augmented bladders to be secondary to local ischemia at the peripheral augmented part. This is not applicable to our case. We postulate that a sudden increase in the intravesical pressure with a pressure pop off in an area of weak detrusor support similar to a small bladder saccule is the cause for

perforation in our patient. The theory of perforation at an area of weak detrusor support might also be applicable to patients with augmented bladders, where rupture at the augmentation anastomosis line might be related to this fact rather than the theory of impaired vascularity and relative ischemia.

In conclusion, we feel that spontaneous perforation of the neuropathic bladder should be suspected in patients presenting with symptoms that might suggest such complications. Irrespective of a history of bladder augmentation, a proactive management of patients with *spina bifida* by a dedicated team should be established in all centers.

## References

1. Bauer SB, Hallett M, Khoshbin S, Lebowitz RL, Winston KR, Gibson S et al. Predictive value of urodynamic evaluation in newborn with myelodysplasia. *JAMA* 1984; 252: 650-654.
2. Carmon M, Nissan A, Pappo I, Perlberg S, Seror D, Haskel Y. Spontaneous rupture of the urinary bladder complicated by extensive fasciitis. The importance of high index of suspicion. *Urol Int* 1994; 52: 38-40.
3. Marcus EL, Prat O. Urinary bladder rupture in an elderly patient - Case Report. *Can Fam Physician* 1995; 41: 1945-1947.
4. Patel RI, Haas C, Spirmak JP, Erhardt C. Spontaneous extraperitoneal bladder rupture. *J Urol* 1998; 159: 2089-2090.
5. Bauer SB, Hendren WH, Kozakewich H, Maloney S, Colodny AH, Mandell J et al. Perforation of the augmented bladder. *J Urol* 1992; 148: 699-703.
6. Elder JS, Snyder HM, Hulbert WC, Duckett JW. Perforation of the augmented bladder undergoing clean intermittent catheterization. *J Urol* 1988; 140: 1159-1163.
7. Rushon HG, Woodard JR, Parrott TS, Jeffs RD, Gearhart JP. Delayed bladder rupture after augmentation enterocystoplasty. *J Urol* 1988; 140: 344-346.
8. Hensele TW, Dean GE. Complications of urinary tract reconstruction. *Urol Clin North Am* 1991; 18: 755-764.
9. Gerharz EW, Turner WH, Kalble T, Woodhouse CRJ. Metabolic and functional consequences of urinary reconstruction with bowel. *BJU Int* 2002; 91: 143-149.
10. Maguire EJ, Woodside JR, Borden TA, Weiss RM. Prognostic value of urodynamic testing in myelodysplastic patients. *J Urol* 1981; 126: 205-208.