

# Radiological management of cerebrospinal fluid rhinorrhea

*Fahad B. Albadr, MD, Ibrahim A. Alorainy, MD.*

---

## ABSTRACT

Cerebrospinal fluid (CSF) rhinorrhea results in high morbidity and mortality if left untreated. Surgical intervention is recommended in such cases; however, success is dependent on correct diagnosis and precise localization of leak site. Imaging plays a very essential and indispensable role. Imaging also plays a very important role in identifying the cause of leak and planning surgery. The radiological investigations used in evaluation of CSF rhinorrhea evolved over time from simple tests to very sophisticated and highly accurate procedures. Correct diagnosis and localization of leak depends on proper selection and adequate technique of radiological examinations. Sound knowledge in the current radiological investigations for CSF rhinorrhea, including the yield, indications, contraindications, complications, and selection, is essential for both treating physician and radiologist.

**Neurosciences 2004; Vol. 9 (3): 158-164**

---

**B**ack in the second century, cerebrospinal fluid (CSF) rhinorrhea was considered a normal physiological release of CSF into the nose via sella and ethmoid air cells.<sup>1</sup> Only in the 19th century was it recognized as abnormal and its anatomical basis was described. In the early 20th century CSF leak was treated surgically.<sup>2</sup> For CSF to enter the nasal cavity there must be a defect in both dura matter and bone.<sup>2</sup> Common sites of leakage are cribriform plate (especially adjacent to the vertical attachment of middle turbinate), and ethmoidal, frontal, and sphenoid sinuses.<sup>3-6</sup> Less common sites include the roof of the petrous bone, posterior wall of internal auditory canal, floor of the middle cranial fossa via the pterygoid recess of the sphenoid sinus, and planum sphenoidale.<sup>2-4,7,8</sup>

Trauma, either direct (80%) or surgical (16%), is generally the most frequent cause of CSF rhinorrhea, while only 4% of cases are spontaneous.<sup>2,4,5,9-11</sup> Cerebrospinal fluid rhinorrhea probably complicates approximately 2-3% of all head injuries and 5-11% of skull base fractures which usually present within 48 hours of trauma.<sup>2,11</sup>

Spontaneous CSF rhinorrhea could be idiopathic or secondary to meningocele, encephalocele, Wegener's granuloma, pituitary tumor, invasive skull base tumor, empty sella, trauma, or radiotherapy.<sup>5,6,12</sup> Idiopathic spontaneous CSF fistulas may occur subsequent to rupture of congenital arachnoid pits or diverticulae which cause thinning of the adjacent bone and subsequent rupture into the adjacent air cavity.<sup>7,13-15</sup> Cerebrospinal fluid rhinorrhea may be further classified to high pressure and normal pressure. Causes of high-pressure rhinorrhea include hydrocephalus, and other causes of chronically raised intracranial pressure. Normal pressure rhinorrhea is caused by congenital anomalies such as meningocele, encephalocele, defect in cribriform plate, and leakage via empty sella.<sup>2</sup>

Continuous and copious leak is seen in spontaneous fistulae, while leak in traumatic fistulae is usually intermittent and scanty. The traumatic fistulae occur predominantly in young males, whereas spontaneous fistulae are seen predominantly in middle-aged females.<sup>2,4-6</sup> In

---

From the Department of Radiology, College of Medicine & King Khalid University Hospital, King Saud University, Riyadh, Kingdom of Saudi Arabia.

Address correspondence and reprint request to: Dr. Ibrahim A. Alorainy, PO Box 9047, Riyadh 11413, Kingdom of Saudi Arabia. Tel. +966 (1) 4671155. Fax. +966 (1) 4671746. E-mail: alorainy@ksu.edu.sa

traumatic CSF rhinorrhea, the interval between trauma and onset of leak varies widely from immediate presentation to several (up to 50) years.<sup>4,9,16</sup> Brain tissue herniating into the dural, bony defect or both prevents the healing process and may be responsible for intermittent long-standing rhinorrhea, which may last for several years.<sup>5</sup> Patients with recurrent rhinorrhea are thought to have intermittent reopening of the fistula. This phenomenon could occur due to nose bowing, Valsalva maneuver, or minor trauma not reported by the patient.<sup>1,13</sup>

Clinical lateralization is not reliable especially in traumatic fistulae due to dislocation of vomer from the crista galli which allows crossing of CSF to the other nostril.<sup>2,17</sup> Patients may present with anosmia, which is more common in the traumatic type. However, normal olfaction does not exclude cribriform plate defect.<sup>2</sup> Spontaneous cessation of CSF leak may occur without surgery, however, this does not indicate healing of the underlying dural tear as some of these patients may present with recurrent intracranial infection at a later date.<sup>2,4,16,18</sup> Bacterial meningitis is the major complication occurring in 50-80% of untreated fistulae especially in the traumatic type.<sup>1,3,5,13,14</sup>

**Non-radiological investigations.** Nasal secretions secondary to allergic rhinitis, mucocoele or retention cyst, lacrimal fluid, or CSF rhinorrhea may not be easily differentiated clinically. Glucose content of a clear nasal discharge was used to differentiate CSF leak from other causes of clear nasal discharge, however, this test requires a relatively large amount of fluid and has poor predictive value with high false positive results reaching up to 75% and probably should not be used.<sup>1,12,19,20</sup> Beta-2 Transferrin is a protein that is highly specific for human CSF. Nasal secretions can be tested for the presence of this protein and not more than 1ml of fluid is required to carry out the test with no need for special handling or refrigeration.<sup>6</sup> This test gained popularity in recent years and superseded all other laboratory tests.<sup>19</sup> The test is considered confirmatory of CSF leak when positive, however, negative result does not exclude CSF leak.<sup>6</sup> Intraoperatively, intrathecal fluorescein injection helps in locating the site of CSF leak during extracranial endoscopic surgery if localization by imaging is inadequate.<sup>21</sup> However, the procedure is complicated by chemical meningitis, seizure, cranial nerve deficit, numbness, extremity weakness, and dysphasia.<sup>21</sup> The use of filtered fluorescein that is specially prepared for intrathecal use has been claimed safe and recommended in cases with negative imaging studies.<sup>6</sup> For optimum use of imaging studies, it is essential to confirm the presence of CSF leak by laboratory analysis before imaging whenever possible.<sup>3</sup>

**Radiological investigations.** In the vast majority of cases with CSF rhinorrhea, the leak ceases in a few weeks time and no radiological investigations are needed. The radiological workup should be limited to patients with persistent or complicated leak. Radiological investigations play a very essential role in the management of CSF rhinorrhea, namely the confirmation of CSF leak; identification of the cause of CSF leak; localization of the site(s) of CSF leak; road-mapping for surgery and; assessment of the intracranial structures. In the past, the radiological examinations available for assessment of CSF rhinorrhea were lacking sensitivity and specificity and much weight was put on intraoperative evaluation. With recent advances in imaging and technology, new examinations with much better sensitivity and specificity became available. The following is a discussion on the old and new modalities followed by a suggested algorithm that helps in appropriate selection of radiological examination for evaluation of CSF rhinorrhea. **Table 1** shows a comparison between the examinations that are in current use.

**Plain films and tomography.** Plain radiography was initially found to be useful in evaluation of extent of fractures at skull base and presence of intracranial air in up to 20% of cases. The use of complex motion tomography allowed smaller defects to be identified in up to 50% of cases.<sup>2,17,22,23</sup> However, plain films and tomography have no use in the assessment of CSF rhinorrhea nowadays in the presence of more accurate cross-sectional modalities such as computed tomography (CT) and magnetic resonance imaging (MRI).

**Digital subtraction cisternography (DSC).** Digital subtraction cisternography was introduced to allow dynamic study of fistula especially in active

**Table 1 -** Comparison between different radiological modalities in CSF rhinorrhea management.

Criteria	RNC	HRCT	CTC	MRC
Confirming leak	Excellent	Not useful	Good	Good
Leak localization	Not useful	Good	Excellent	Good
Dependency on leak activity	Dependant	Not dependant	Very dependant	Dependant
Ionizing radiation	Low	High	High	None
Dependency on patient position during imaging	Dependant	Not dependant	Very dependant	Very dependant
Complications	Occasional	None	Frequent	None
Invasiveness	Invasive	Non-invasive	Invasive	Non-invasive
RNC - radionuclide cisternography, HRCT - high-resolution computed tomography, CTC - computed tomography cisternography, MRC - magnetic resonance cisternography, CSF - cerebrospinal fluid				

cases. This examination is carried out while the patient is in prone position with head 20° below the horizontal line. A 22 gauge spinal needle is introduced at C1/C2 level and 8 ml of non-ionic contrast material is administered intrathecally under real time digital fluoroscopy control. Contrast material movement in the subarachnoid space is observed until it reaches the suprasellar cistern and subfrontal region. In the presence of active leak, contrast material will be seen tracking outside the intracranial cavity. In cases of inactive leak, CSF pressure may be artificially raised by injecting 10ml of normal saline. The pathway of leakage is recorded in lateral and antero-posterior projections.<sup>12</sup> This technique is invasive and does not provide precise spatial localization of the fistula like CT and MRI. For these reasons, it did not gain popularity.

**Radionuclide cisternography (RNC).** In RNC, the CSF spaces are filled with radioactive material via intrathecal (lumbar or cisternal) injection using 1-2 mCi of 99mTc-DTPA. The patient is positioned in the head-down position to allow tracer to flow intracranially. Multiple images in different positions are obtained after approximately 3 hours from injection, and any tracer activity extracranially is documented on different projections and correlated anatomically.<sup>1</sup> It is very crucial to obtain images in different positions including: prone, supine, lateral, and head-down positions since this has significant impact on the yield of the examination.<sup>20</sup> In fact, one of the advantages of RNC over CTC and MRI is its ability to obtain images in virtually any patient position allowing imaging in the position that provokes leak. Obviously, the precise anatomical location cannot be pinpointed on this examination due its limited spatial resolution.<sup>5,23,24</sup> Since this examination can detect only active leak with reasonable amount of leaking CSF, it has been complemented by the RNC counting technique. In this technique, several nasal numbered pledges are placed in the nose at the sphenoethmoidal recess, olfactory cleft and in the middle meatus before starting the study.<sup>20</sup> After imaging, the pledges are removed and a blood sample is taken at the same time. The activity in each pledge is measured and compared with that of the blood sample. The normal ratio (radionuclide count in pledges/radionuclide count in the blood sample) should be less than 0.37.<sup>20,25</sup> The idea behind this is that radionuclide is normally absorbed from CSF into the blood and reaches all body tissues including the nasal mucosa and secretions. Only ratios above 0.37 are considered due to direct leak of radionuclide-containing CSF. The pledge with the highest count is assumed to have been nearest to the leak or the ostium of the sinus with leak. This is obviously one of the shortcomings of this examination because a positive pledge at the middle meatus cannot tell whether the leak is from

frontal sinus or anterior ethmoid air cells since they drain to the same site.<sup>5,23</sup> However, the counting technique has better sensitivity than the imaging technique, especially in small defects and in intermittent leaks. If there is no active leak during examination, the RNC is likely to be negative. To overcome this limitation some investigators recommend using over pressure technique by intrathecal injection of artificial CSF, or less preferably normal saline.<sup>25</sup> The overpressure technique cuts the time of the procedure to less than one hour because the tracer fills the cisterns more quickly and allows a semi real time control on the procedure. The use of Indium-111-labeled DTPA as a radioactive material is claimed to be helpful in cases of inactive leak. Indium-111 has a longer half life, hence, it allows longer imaging time which can extend to 3 days.<sup>1</sup> By extending the imaging time, the chance of detection of intermittent leak is increased. However, the disadvantages of this technique include higher radiation dose and patient discomfort from presence of nasal pledges for a longer time.

**CT Cisternography (CTC).** CT cisternography (CTC) was introduced in 1977.<sup>18,22</sup> This examination is carried out through an intrathecal injection of non-ionic contrast medium in the lumbar region or at C1/C2 level. The later approach allows less dilution of contrast medium, hence, better opacification of CSF and less amount of contrast medium to be injected.<sup>17</sup> Some authors recommend obtaining CT of the brain particularly in cases of spontaneous CSF rhinorrhea before performing CTC to exclude causes such as intracranial mass or hydrocephalus that contraindicates lumbar puncture,<sup>2</sup> however, careful clinical examination obviates the routine need for this step. The recommended volume of contrast medium is 5-7ml for children and 8-10ml for adults of 240-300 mg iodine/ml concentration.<sup>1,7</sup> The patient is kept in head-down position to facilitate movement of contrast material into the subarachnoid spaces of the brain. While the patient is in the prone position, direct contiguous 1-3mm-thick coronal sections covering the region from the anterior most part of the frontal sinuses to the posterior most part of the sphenoid sinus are obtained. Depending on the clinical setting and the cause of CSF rhinorrhea, sections may be extended posteriorly to cover the mastoid region since leak at this site may present as CSF rhinorrhea through flow via the eustachian tube.<sup>2,25</sup> This step should also be considered if no defect is identified anteriorly. Nasal pledges may be used to help in leak detection and lateralization if the leak is minimal.<sup>2,3,14,22</sup> It has also been shown that Valsalva maneuver during scanning increases detection rate.<sup>2,6,13</sup> Controversial methods have been described to increase the sensitivity of this test, including head-hanging and

the overpressure techniques.<sup>24-26</sup> The images should be printed/viewed at window setting that differentiates best between cortical bone and contrast-opacified CSF and between blood within the paranasal sinuses and the dye, example of which is window level at 200 and window width at 4000.<sup>24,11</sup> The study is considered positive if contrast material passes through a bone/dural defect or if there is a bone defect with contrast material in the ipsilateral sinus or pledge (**Figure 1**). However, the presence of a bone defect alone or contrast medium in the ipsilateral nasal pledges makes the study equivocal. The study is considered negative if there is no bony defect and no extra cranial extension of contrast material.<sup>1,2,4,9,22</sup> The presence of sulcal deformity is a significant finding in localizing the site of the leak especially in posttraumatic cases.<sup>1,4,9</sup> Technical problems such as volume averaging and metallic artifacts from dental work may degrade the quality of the study.<sup>11</sup>

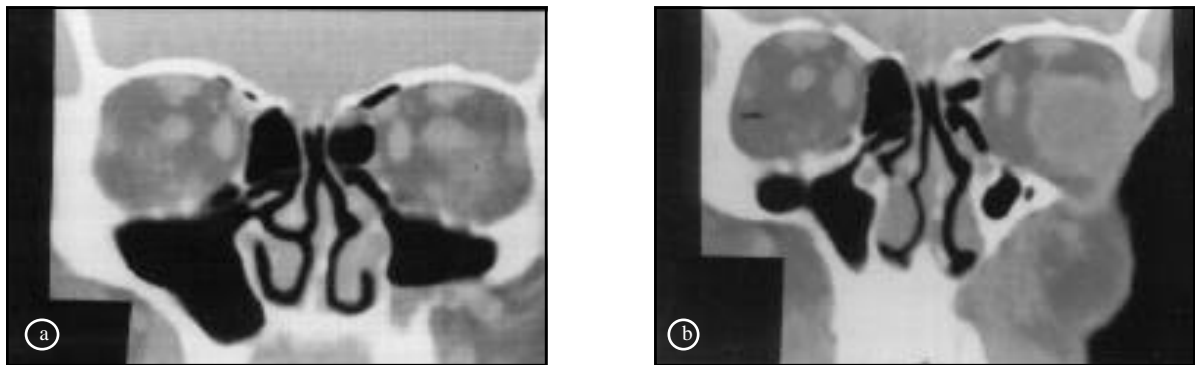
For more than a decade CTC was considered the examination of choice for CSF fistula especially during the leaking period.<sup>2-4,6,12-14,19,25</sup> Overall accuracy of CTC ranges from 30-65% and increases up to 85-100% when the study is carried out during active leak. However, the yield of CTC is generally lower in cases of inactive leak.<sup>3,4,11,13</sup> The following are factors that increase CTC yield: scanning during leak; patient position that provokes leak; Valsalva maneuver; using the same window width and level in pre and post intrathecal contrast-enhanced CT; using helical CT and; adequate anatomical coverage. CT cisternography was thought better than CT alone because dural tear may be at some distance from the bone defect and fine fractures may not be seen on plain CT.<sup>5,13,22</sup> Furthermore, CTC identifies the leaking defect in cases with multiple defects which are not possible using CT alone.<sup>1</sup> In addition, CTC provides direct evidence of leak while the evidence from CT alone is indirect.

However, the study is invasive and time consuming and sometimes complicated by headache.<sup>3</sup>

Computed tomography cisternography is contraindicated in active meningitis and in patients with elevated intracranial pressure due to intracranial mass or head injury.<sup>2-4</sup> The complications associated with the newer non-ionic contrast media is much lower than those of the older ones. However, transient adverse reactions (headache, nausea, vomiting, perceptual alteration, and seizures) are reported complications.<sup>4,6</sup> Because coronal sections only, can not detect defects in the posterior walls of frontal and sphenoid sinuses and lack of reliability of clinical presentation in pointing the site of leak, some investigators recommend routine additional scanning of the anterior and middle cranial fossae in the axial plane.<sup>16</sup> The major disadvantage of this approach is the substantial increase in the radiation dose to the lens. The radiation dose received by the lens from axial protocol is approximately 20 times the dose from the coronal plane.<sup>16</sup> Furthermore, in a study of 15 patients with spontaneous sphenoid sinus fistula the defects were in a location best depicted by the coronal plane.<sup>14</sup> Because of the invasiveness of the procedure, its complications, and the exposure to radiation, it is advised to reserve CTC as a second choice for postoperative cases and cases with negative non-invasive examinations.<sup>4</sup>

#### **Magnetic resonance cisternography (MRC).**

Magnetic resonance cisternography is basically a heavily weighted T2 sequence that depicts the presence of fluid in the region of skull base. The examination is usually carried out in the supine position and images are taken in 3 planes (axial, coronal and sagittal) to maximize the chance of defect detection. The recommended slice thickness is 3-4 mm with 0.3-0.4 mm inter-slice gap. Interleaved images allow contiguous imaging with



**Figure 1** - Forty-five-year-old man with post-traumatic CSF rhinorrhea. **a)** Coronal CT before contrast material injection shows a soft tissue density in the left ethmoid sinus adjacent to the junction of ethmoidal fovea and attachment of the middle turbinate at the frontoethmoidal recess. **b)** CT cisternography shows leak of contrast material into the region of the mass indicating CSF leak. Note that the intracranial CSF spaces are filled with contrast material. CSF - cerebrospinal fluid

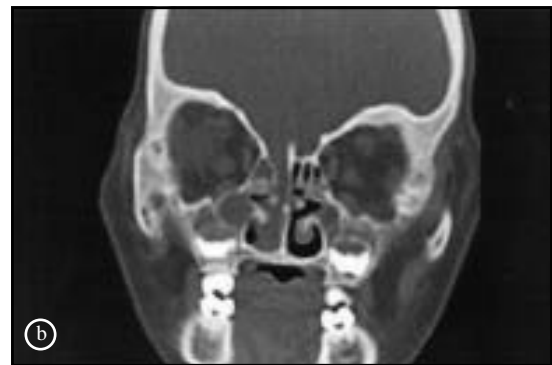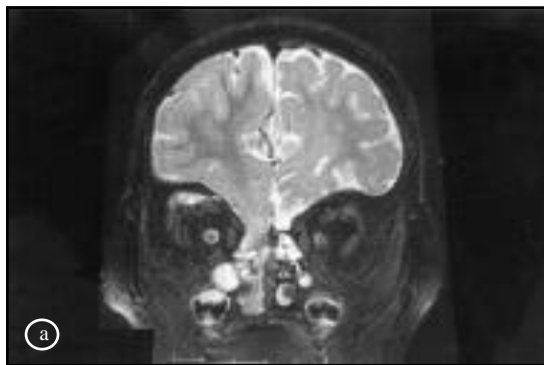
no inter-slice gap. Fat saturation is optional.<sup>13,24</sup> Fast spin echo sequence, compared to conventional spin echo, is associated with less magnetic susceptibility artifacts between air-filled paranasal sinuses and brain and allows quicker imaging, thus reducing motion artifacts.<sup>27</sup> Because sino-nasal mucosa has a high signal on T2WI, some authors advice to use T1WI before and after intravenous gadolinium injection to differentiate enhancing mucosa from leaking non-enhancing CSF signals.<sup>11,24</sup> Changing position of the patient (prone, supine and lateral decubitus) may give further supportive findings by demonstrating the increase in the amount of CSF signal in the sino-nasal cavity especially in active fistulae if that particular position provokes leak, however, positions other than supine are more subject to motion artifacts and uncomfortable for the patient.<sup>3,4,13,28</sup>

Magnetic resonance cisternography is considered positive if there is herniation of brain tissue (seen usually in larger defects) or arachnoid through a bone defect; or if there is CSF signal in the paranasal sinuses continuous with CSF in the subarachnoid space (**Figure 2a**). If CSF signal in the paranasal sinuses is not continuous with the subarachnoid space and not enhancing with Gadolinium on T1WI, the diagnosis of fistula is suspected.<sup>3,4,11,13,24,28</sup> Other minor criteria include basal gliosis, empty sella, and sulcal deformity due to adhesions close to the dural-bone defect especially in traumatic cases.<sup>4,14</sup> The relation of empty sella to CSF rhinorrhea is an area of debate. Some authors suggest that empty sella is common enough in the general population to be expected as an incidentally, co-existent finding.<sup>4</sup>

Magnetic resonance cisternography has the advantage of being non-invasive and, unlike CTC, not dependent on active leakage for positive diagnosis.<sup>1-4,12,29</sup> Magnetic resonance cisternography

is superior to CTC in cases of multiple dural defects and in cases with inactive (intermittent) leakage and also superior to CT especially if the dural defect is less than 2 mm.<sup>4,28,29</sup> Magnetic resonance cisternography sensitivity ranges from 70-85% in detection of the site of CSF leakage,<sup>3</sup> reaching up to 100% in some studies.<sup>11,24</sup> Magnetic resonance cisternography shows continuous CSF path in cases of CSF rhinorrhea between subarachnoid space and sino-nasal cavity even in patients with inactive leak, while in CTC continuous path of contrast medium between subarachnoid space and sino-nasal cavity is seen in only approximately 50% of patients.<sup>29</sup> This is probably related to the activity of the leak during imaging which affects the yield of CTC but not MRC. To improve the sensitivity of MRC, this examination has been performed after intrathecal contrast material injection (contrast-enhanced MRC).<sup>8,30,31</sup> After acquiring fat saturated T1-weighted images in multiple planes, intrathecal injection of 1 ml gadolinium diluted in 4 ml normal saline is made and the same sequences repeated. Once again, the patient maybe positioned in a way that provokes leak (including prone and decubitus positions). This examination is principally similar to CTC and equally invasive; however, enhanced MRC has the advantage of no ionizing radiation and the complications of intrathecal gadolinium is apparently less than intrathecal iodinated contrast media. It is worth mentioning that gadolinium is not yet approved for routine intrathecal administration worldwide, although the preliminary results of experimental studies on animals and humans indicate that it is safe.<sup>8,31,32</sup>

With newer MR technology, and in the absence of contraindications to exposure to magnetic field, MRC is recommended to be the first investigation in localizing CSF fistulae because of its comparable



**Figure 2** -Two-year-old girl with CSF rhinorrhea post fall from the third floor. **a)** Coronal T2-weighted MR image shows herniation of brain and meninges through a large defect in the right cribriform plate and ethmoidal fovea. Note the sulcal deformity secondary to the herniation. **b)** Coronal CT shows herniation of brain and meninges through the defect in the right cribriform plate and ethmoidal fovea. CSF - cerebrospinal fluid

accuracy to CTC. Some authors suggest that MRC alone or in conjunction with HRCT is a viable alternative to invasive CTC.<sup>3,4</sup> Moreover, many authors believe that MRC should be sufficient for surgical planning.<sup>4,6</sup>

**High resolution CT (HRCT).** The advanced technology used in the new CT scanners allows very thin sections (1 mm) to be obtained throughout the area of interest in a very short time and has made HRCT an important option in the assessment and localization of CSF leak. Direct coronal and axial sections through the floor of the anterior and middle cranial fossae are obtained with slice thickness of 1-3 mm and bone algorithm.<sup>1,3,16</sup> Thinner sections overcome the problem of partial volume averaging and allow detection of smaller defects and better reformation in the sagittal plane. The coronal images are obtained in the extended neck prone position which enhances the chance of CSF leak detection because the leak is usually provoked in this position. The axial images are helpful in temporal bone evaluation and in evaluation of posterior walls of the frontal and sphenoid sinuses, but it will increase radiation dose to the eye.<sup>3,16</sup> All CT images have to be viewed on soft-tissue and bone windows. The study is considered positive in the presence of a bone defect with communicating air or CSF density or presence of extracranial herniation of brain tissue or meninges (**Figure 2b**).<sup>1,14</sup> The margins of old fractures may show sclerosis.<sup>1,3,14</sup> In cases with multiple fractures at skull-base, the presence of hematoma or fibrous tissue adjacent to a fracture may suggest CSF fistula site.<sup>3</sup> Unlike CTC, the yield of HRCT is independent on leak activity at the time of imaging.<sup>3,16</sup> The limitations of this technique include partial volume averaging that can cause false negative and false positive results, beam-hardening artifact from dental work, and inability to differentiate between CSF and blood, mucous, or pus in the paranasal sinuses.<sup>1,6</sup> As mentioned before, the HRCT provides indirect evidence of leak, while the evidence from CTC is a direct one. There is always an assumption in HRCT that the leak site is at or close to the fracture site, which is not necessarily always true, especially in cases with multiple fractures.<sup>3,13,17</sup> Many authors suggest HRCT as a first line of investigation since neither CTC nor RNC was positive in absence of bone defect.<sup>1,3,16</sup> However, the combination of HRCT and MRC (both are non-invasive) is accurate in up to 96% of cases.<sup>3</sup> In a group of 30 patients with CSF leak and positive HRCT, both CTC and RNC failed to show the leak site in 10 of them and none of the 30 patients had positive CTC or RNC in the absence of defect on HRCT.<sup>1</sup>

**Radiological management algorithm.** When encountered with a confirmed or suspected case (history of recurrent meningitis; for example) of CSF rhinorrhea we and several other authors<sup>3,4,6</sup>

recommend starting with MRC as the first line of investigation. High resolution CT may be carried out if MRC is negative or not adequate for surgical planning and guidance. Our experience with CTC and its associated complications and inconvenience reserve this examination for complicated cases (such as multiple skull base fractures and a postoperative recurrent leak) and for cases with confirmed or highly suspected CSF leak and negative HRCT and MRC. The role of RNC in localizing the site of leak is superseded by HRCT, CTC, and MRC and its role nowadays is limited to confirmation of leak. Plain films, tomograms, and DSC have no place in current practice. It is prudent to say that the outcome of radiological management of CSF rhinorrhea is dependent on careful selection of imaging tool, adequate technique, and correct interpretation. In addition, the radiological management of CSF rhinorrhea has a very significant impact on mortality and morbidity associated with this derangement.

## References

1. Stone JA, Castillo M, Neelon B, Mukherji SK. Evaluation of CSF leaks: high-resolution CT compared with contrast-enhanced CT and radionuclide cisternography. *AJNR Am J Neuroradiol* 1999; 20: 706-712.
2. Colquhoun IR. CT cisternography in investigation of cerebrospinal fluid rhinorrhea. *Clin Radiol* 1993; 47: 403-408.
3. Shetty PG, Shroff MM, Sahani DV, Kirtane MV. Evaluation of high-resolution CT and MR cisternography in the diagnosis of cerebrospinal fluid fistula. *AJNR Am J Neuroradiol* 1998; 19: 633-639.
4. Gupta V, Goyal M, Mishra N, Gaikwad S, Sharma A. MR evaluation of CSF fistulae. *Acta Radiol* 1997; 38: 603-609.
5. Özgen T, Tekkök IH, Cila A, Erzen C. CT cisternography in evaluation of cerebrospinal fluid rhinorrhea. *Neuroradiology* 1990; 32: 481-484.
6. Land NJ, Savvy L, Lloyd G, Hoard D. Optimum imaging and diagnosis of cerebrospinal fluid rhinorrhea. *J Laryngol Otol* 2000; 114: 988-992.
7. Yeats A, Blunenkopf B, Drawer VP, Wildings IH, Osborn D, Heinz ER. Spontaneous CSF Rhinorrhea arising from the middle cranial fossa: CT demonstration. *AJNR Am J Neuroradiol* 1984; 5: 820-821.
8. Wenzel R, Leppien A. Gadolinium-myelocisternography for cerebrospinal fluid rhinorrhea. *Neuroradiology* 2000; 42: 874-880.
9. Fagerlund M, Liliequist B. Intermittent cerebrospinal liquorhea. *Acta Radiol* 1987; 28: 189-192.
10. Murata Y, Yamada I, Isotani E, Suzuki S. MRI in Spontaneous Cerebrospinal fluid rhinorrhea. *Neuroradiology* 1995; 37: 453-455.
11. Johnson DBS, Bernan P, Toland J, O'Dwyer AJ. Magnetic resonance imaging in the evaluation of cerebrospinal fluid fistulae. *Clin Radiol* 1996; 51: 837-841.
12. Wakhloo AK, van Velthoven V, Schumacher M, Krauss JK. Evaluation of MR Imaging, digital subtraction cisternography, and CT cisternography in diagnosing CSF fistula. *Acta Neurochir* 1991; 111: 119-127.
13. El Gammal T, Sobol W, Wadlington VR, Sillers MJ, Crews C, Fisher WS III, et al. Cerebrospinal fluid fistula: detection with MR cisternography. *AJNR Am J Neuroradiol* 1998; 19: 627-631.

14. Shetty PG, Shroff MM, Fatterpekar GM, Sahani DV, Kirtane MV. A retrospective analysis of spontaneous sphenoid sinus fistula: MR and CT findings. *AJNR Am J Neuroradiol* 2000; 21: 337-342.
15. Bjerre P, Lindholm J, Gyldensted C. Pathogenesis of non-traumatic cerebrospinal fluid rhinorrhea. *Acta Neurol Scand* 1982; 66: 180-190.
16. Lloyd MNH, Kimber PM, Burrows EH. Post-traumatic cerebrospinal fluid rhinorrhea: modern high-definition computed tomography is all that is required for effective demonstration of the site of leakage. *Clin Radiol* 1994; 49: 100-103.
17. Ahmadi J, Weiss MH, Segall HD, Schultz DH, Zee CS, Giannotta SL. Evaluation of cerebrospinal fluid rhinorrhea by metrizamide computed tomographic cisternography. *Neurosurgery* 1985; 16: 54-60.
18. Drayer BP, Wilkins RH, Boehnke M, Horton JA, Rosenbaum AE. Cerebrospinal fluid rhinorrhea demonstrated by metrizamide CT Cisternography. *AJR Am J Roentgenol* 1977; 129: 149-151.
19. Yamoamoto Y, Kunishio K, Sanami N, Yamamoto Y, Satoh T, Suga M, et al. Identification of CSF fistulas by radionuclide counting. *AJNR Am J Neuroradiol* 1990; 11: 823-826.
20. Jones NS, Becker DG. Advances in the management of CSF leaks. *BMJ* 2001; 322: 122-123.
21. Moseley JL, Carton CA, Stern WE. Spectrum of complications in the use of intrathecal fluorescein. *J Neurosurg* 1978; 48: 765-767.
22. Manelfe C, Cellier P, Sobel D, Prevost C, Bonafé A. Cerebrospinal fluid rhinorrhea: evaluation with metrizamide cisternography. *AJR Am J Roentgenol* 1982; 138: 471-476.
23. Lantz EJ, Forbes GS, Brown ML, Laws ER Jr. Radiology of cerebrospinal fluid rhinorrhea. *AJR Am J Roentgenol* 1980; 135: 1023-1030.
24. Eljamel MS, Pigeon CN. Localization of inactive cerebrospinal fluid fistulas. *J Neurosurg* 1995; 83: 795-798.
25. Curnes JT, Vincent LM, Kowalsky RJ, McCartney WH, Staab EV. CSF rhinorrhea: detection and localization using overpressure cisternography with Tc-99m-DTPA. *Radiology* 1985; 154: 795-799.
26. Rothfus WE, Deeb ZL, Daffner RH, Prostko ER. Head-hanging CT: an alternative method for evaluating traumatic CSF rhinorrhea. *AJNR Am J Neuroradiol* 1987; 8: 155-156.
27. Jones KM, Mulkern RV, Schwartz RB, Oshio K, Barnes PD, Jolesz FA. Fast spine-echo MR imaging of the brain and spine: current concepts. *AJR Am J Roentgenol* 1992; 158: 1313-1320.
28. Gupta V, Goyal M, Mishra NK, Sharma A, Gaikwad SB. Positional MRI: a technique for confirming the site of leakage in cerebrospinal fluid rhinorrhea. *Neuroradiology* 1997; 39: 818-820.
29. Eberhardt KEW, Hollenbach HP, Deimling M, Tomandl BF, Huk WJ. MR cisternography: a new method for the diagnosis of CSF fistulae. *Eur Radiol* 1997; 7: 1485-1491.
30. Zeng Q, Xiong L, Jinkins JR, Fan Z, Liu Z. Intrathecal gadolinium-enhanced MR myelography and cisternography: a pilot study in human patients. *AJR Am J Roentgenol* 1999; 173: 1109-1115.
31. Reiche W, Komenda Y, Schick B, Grunwald I, Steudel WI, Reith W. MR cisternography after intrathecal Gd-DTPA application. *Eur Radiol* 2002; 12: 2943-2949.
32. DiChiro G, Garton ME, Frank JA, Dietz MJ, Gansow OA, Wright DC et al. Cerebrospinal fluid rhinorrhea: depiction with MR cisternography in dogs. *Radiology* 1986; 160: 221-222.