Contribution of immunological and genetic investigations to improve classification of patients with congenital muscular dystrophy

Nacim Louhichi, *PhD,* ***Chahnez Triki,*** *MD,* ***Mariem Meziou,*** *MD,* ***Souad Rouis,*** *PhD,* ***Hammadi Ayadi,*** *PhD,* ***Faiza Fakhfakh,*** *PhD.*

ABSTRACT

Objectives: To minimize the uncertainty in clinical diagnosis and improve the classification of 14 Tunisian patients belonging to 12 families and affected with congenital muscular dystrophy (CMD).

Methods: Fourteen patients belonging to 12 unrelated families originating from the south of Tunisia and affected with CMD were clinically examined between 1990 and 2001 in the neurology service of Chu Habib Bourguiba, Sfax, Tunisia. Immunohistochemical and western blot analyses were used to explore protein expression in muscular biopsies and homozygosity mapping using microsatellite markers for the genetic study. These analyses were performed in the human molecular genetics laboratory.

Results: Among the patients tested with anti-merosin antibodies, 3 showed total laminin-α2 deficiency and the remaining patients showed partial laminin-α2 deficiency. All patients expressed normally α-sarcoglycan, β-dystroglycan and dystrophin except 2 showing reduction of expression in α-sarcoglycan and β-dystroglycan. Linkage analysis, performed for 8 families, was compatible with linkage to the LAMA2 gene for only 2.

Conclusion: Our results showed that clinical and immunohistochemical analyses have allowed classification of only 3 patients, immunohistochemical and genotyping studies have contributed to the classification of 7 patients. In the remaining cases, there is no evident classification due to the lack of the genetic exploration. Our results also confirmed the broad spectrum of phenotypes associated with a defect in laminin-α2.

Neurosciences 2004; Vol. 9 (4): 247-253

Congenital muscular dystrophies (CMDs) are a heterogeneous group of neuromuscular disorders transmitted in an autosomal recessive pattern. Their severe manifestations consist of muscle weakness and hypotonia at birth.[1] Muscle biopsies show dystrophic features with abnormal variation in fibre size and variable degrees of connective tissue.[2] Several sub-groups of CMD have been defined on clinical, immunocytochemical and genetic grounds. Some CMDs show clinical features predominantly derived from the muscle dystrophy called classical CMD (MDC1A). Regarding classical CMD, a primary deficiency in the laminin-α2 chain (merosin) occurs in 40-50% of cases[3,4] and is caused by defects in the laminin-α2 gene (LAMA2) on chromosome 6q22.[5,6] Other forms, however, are associated with severe mental retardation and structural brain or cerebellar abnormalities of the central nervous system (CNS). These forms include the Fukuyama type CMD

From the Laboratoire de Génétique Moléculaire Humaine (Louhichi, Rouis, Ayadi, Fakhfakh), Faculté de Médecine de Sfax and Service de Neurologie (Triki, Meziou), Chu Habib Bourguiba, Sfax, *Tunisia*.

Received 17th January 2004. Accepted for publication in final form 12th April 2004.

Address correspondence and reprint request to: Dr. Nacim Louhichi, Laboratoire de Génétique Moléculaire Humaine, Faculté de Médecine de Sfax, Sfax, 3029, *Tunisia*. Tel. +216 (74) 246946. Fax. +216 (74) 246946. E-mail: nacim.louhichi@fss.rnu.tn

(FCMD), caused by a mutation in FKT1, Walker-Warburg syndrome (WWS), caused by a mutation in POMT1 and muscle-eye-brain disease (MEB), caused by a mutations in POMGnT1 genes.[7-12] The remaining CMD forms with or without brain abnormalities may be classified in subgroups with a normal laminin-α2 expression and those with a secondary deficiency of laminin-α2 not due to defect in the LAMA2 gene. In fact, a secondary laminin-α2 deficiency has been described in a CMD form with calf hypertrophy localized on chromosome 1q42 (MDC1B),[13] in MDC1C localized on chromosome 19[14] and also in FCMD[15] and MEB[16] but not in WWS.[15] In addition to the laminin-α2 deficiency, other deficiencies in muscular protein complex were reported in CMD such as those in dystrophin, dystrophin associated glycoprotein (DAG) and α-dystroglycan.[17-20] Therefore, regarding the phenotype heterogeneity in CMD, the difficulty in establishing a differential diagnosis can be overcome by using a complete immunohistochemical study and genotyping. In addition, variability in clinical and immunocytochemical findings of CMD needs further studies using several antibodies against different regions of laminin-α2 and towards proteins belonging to the matrix complex of muscular cells. These studies aim at elucidating some correlation between immunocytochemical changes and severity of clinical phenotype.[21]

To minimize the uncertainty in clinical diagnosis and to improve classification of 14 Tunisian patients affected by CMD and belonging to 12 unrelated families, we have used immunohistochemical analysis and genetic study. Our results show that clinical and immunohistochemical analyses have allowed classification of only 3 patients, immunohistochemical and genotyping studies have enabled us to classify 7 patients. In the remaining cases there is no evident classification because of the lack of genetic exploration. Our results also confirm the broad spectrum of phenotypes associated with deficiency in laminin-α2.

Methods. Fourteen patients belonging to 12 unrelated families originating from Southern Tunisia and affected with CMD were examined between 1990 and 2001. Diagnosis of CMD was made according to the clinical criteria as reported elsewhere.[22] Clinical and radiological investigations were performed for these patients.

Immunohistochemistry. Muscle specimens were studied by conventional histological and immunohistochemical methods.[23] Expression of laminin-α2, dystrophin (dys-2), α-sarcoglycan (DAG 50) and β-dystroglycan (DAG 43) were evaluated using commercial monoclonal antibodies recognizing: human merosin 80 kDa fragment toward C-terminal (mAb 1922 Chemicon, Temecula CA), human merosin 300 kDa fragment toward the amino-terminal (NLC-merosin Novocastra), dystrophin (NLC-DYS2 Novocastra), β-dystroglycan (NLC-43DAG Novocastra) and α-sarcoglycan (NLC-50DAG Novocastra). Dilutions were carried out in phosphate-buffered saline 1:500; 1:50; 1:50; 1:50; and 1:50. All primary antibodies were applied for one hour and revealed with an appropriate fluorescein isothiocyanate (FITC)-conjugated secondary antibody (FITC-conjugated rabbit anti-mouse immunoglobulins DAKO).[24]

Immunoblotting. Laminin-α2 expression by immunoblot was evaluated using the 80 kDa monoclonal antibody against C-terminal fragment of laminin-α2. Muscle cryosections were solubilized in treatment buffer.[25] The nitrocellulose transfers were stained with the primary anti-80 kDa fragments of laminin-α2 antibody. Dilution was the same as that used in immunohistochemical analysis. Primary incubation with this antibody was followed by anti mouse immunoglobulin G (IgG) peroxidase conjugate (IgG H+L code 75031 Sanofi Diagnostics Pasteur) and revealed by ECL™ Western blotting detection reagents kit (Amersham-biotech). Omission of the first antibody was routinely performed as a separate control in order to check for non-specific staining of the applied secondary antibody.[26]

Genetic analysis. Blood samples were collected from 10 individuals belonging to 8 families after informed consent. Nuclear DNA was extracted from blood lymphocytes using a standard phenol-chloroform technique from 10 ml of blood.[27] Polymorphic markers specific of the LAMA2 locus: D6S1715, D6S407, D6S1705, D6S1620, and D6S1572[6] were used. Polymerase chain reaction amplification was carried out in 50 ml with 60 ng of genomic DNA, 1mM of each primer, 125 mM deoxyribonucleoside triphosphates, 1.5 mM magnesium chloride, 5 mM potassium chloride, 10 mM Tris-hydrochloric acid, pH 8.8 and 1U of Taq DNA polymerase. Polymerase chain reactions were performed for 35 cycles: initial denaturation at 94°C for 10 minutes; followed by 94°C for 30 seconds, annealing at 55°C for 40 seconds and extension at 72°C for 40 seconds; final extension for 5 minutes is necessary. Polymerase chain reaction products were analyzed on 6% denaturing polyacrylamide gel, transferred onto N+ Hybond membrane (Amersham Pharmacia Biotech) and hybridized with a poly AC probe labeled with $\alpha^{32}P$. Linkage analyses were performed using the homozygosity mapping.

Results. ***Clinical findings.*** The main clinical and radiological investigations of the 14 patients are

Table 1 - Clinical, paraclinical and genetic data of 14 Tunisian patients.

Family number	Case no/ Sex	Age at onset	Maximum motor ability	Pattern of weakness	Contractures	Intellect	Cerebral MRI/ T2 weighted image	CK value UI/L	Linkage to LAMA2
1	1/F	birth	sitting	+	-	NL	WMC	665	linked
2	2/M	birth	sitting	++	-	NL	ND	3050	excluded
2	3/F	birth	sat unsupported	+	+++	mentally retarded	WMC+CC	7330	excluded
3	4/M	birth	sitting	++	++	NL	ND	1320	ND
4	5/F	birth	sitting	+	++	NL	ND	413	ND
5	6/M	3 months	sitting	++	++	NL	WMC	912	linked
5	7/M	birth	sitting	++	++	NL	WMC	541	linked
6	8/F	4 months	sat unsupported	+	+++	mentally retarded	WMC+CC	2978	excluded
7	9/F	2 months	sat unsupported	++	+++	NL	ND	2600	excluded
8	10/F	birth	sat unsupported	+	+++	mentally retarded	WMC+CC	4000	excluded
9	11/F	birth	sitting	+	+++	NL	WMC+CC	254	ND
10	12/M	birth	sat unsupported	++	+++	mentally retarded	WMC+CC	5500	excluded
11	13/F	birth	sitting	++	+	NL	WMC	633	excluded
12	14/M	birth	sat unsupported	+	-	NL	ND	67	ND

M - male, F - female, NL - normal, ND - not determined, CK - creatine kinase, WMC - white matter changes, CC - cerebellar cysts,
Pattern of weakness: + - generalized with proximal predominancy, ++ - generalized
Contractures: - absent, + - localized, ++ - multiples and moderate, +++ - multiples and severe

Table 2 - Western Blot and immunofluorescence analyses of expression of merosin and expression of dystrophin, α-sarcoglycan and β-dystroglycan on muscle cells from 14 patients with CMD.

Family number	Case no.	IF 80 kDa (merosin)	IF 300 kDa (merosin)	WB 80 kDa (merosin)	IF β-dystroglycan	IF α-sarcoglycan	IF dystrophy	Linkage to LAMA2
1	1	+/-	-	-	+	+	+	linked
2	2	+/-	ND	+	+/-	ND	ND	excluded
2	3	-	+/-	ND	+	-	+/-	excluded
3	4	+/-	ND	+	+	ND	ND	ND
4	5	-	ND	-	+	ND	ND	ND
5	6	-	-	-	ND	+	+	linked
5	7	+/-	-	-	+	+	+	linked
6	8	+	-	ND	+	+	+	excluded
7	9	+/-	-	ND	ND	+	+	excluded
8	10	+/-	-	-	ND	+	+	excluded
9	11	+	+	ND	+	+	+	ND
10	12	+	+/-	ND	+	+	+	excluded
11	13	-	-	-	+	+	+	excluded
12	14	+	ND	+	+	ND	ND	ND

CMD - congenital muscular dystrophy, ND - no data
80kDa - antibody against human merosin 80 kDa fragment, 300 kDa - Antibody against human merosin 300 kDa fragment,
+ - presence, - absence, +/- presence of continued or discontinued fluorescence on a few muscle fibers
IF - Immunofluorescence, WB - Western Blot

summarized in **Table 1**. Note the severe phenotype of patients 3, 8, 10, 11 and 12 who showed severe psychomotor retardation with unsteady head control, inability to stand or walk, marked delay in the language acquisition, mental retardation (except for patient 11) and very high creatine kinase levels. Cerebral MRI revealed white matter change and cerebellar cysts in these patients'. Patients one, 6, 7 and 13 showed classical CMD features with weakness, variable contractures and white matter changes without mental retardation. Patients 2, 4, 5, 9 and 14 showed CMD features with normal intellect and with contractures in cases 4, 5 and 9. Cerebral MRI exploration was not performed for these patients.

Immunohistochemical and western blot analyses. For 10 patients, the study of laminin-α2 expression was performed using the 2 antibodies directed against anti-80 and anti-300 kDa fragments of laminin-α2 **(Table 2).** In this group, 2 patients (patients 6 and 13) showed no Laminin-α2 immuno-staining in muscle fibre surfaces with both anti-80 and anti-300 merosin fragments antibodies. Immunoblot analysis with the 80 kDa antibody did not reveal any specific laminin-α2 band for these patients **(Figure 1).** Seven patients (one, 3, 7, 8, 9, 10 and 12) showed a partial laminin-α2 expression. In fact, in patients one, 7, 9 and 10, laminin-α2 was partially revealed with the anti-80 kDa antibody. For these patients, there was no immunostaining on muscle fibres with the anti-300 kDa antibody. Immunoblot analysis with the anti-80 kDa antibody did not show any specific bands (**Table 2, Figure 1**).

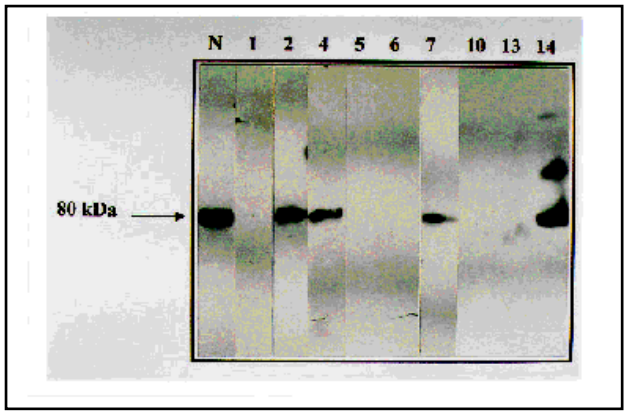

Figure 1 - Western blot of laminin-α2 with antibody to 80 kDa fragment. Lane 1, normal control; lane 2, patient 1; lane 3, patient 2; lane 4, patient 4; lane 5, patient 5; lane 6, patient 6; lane 7, patient 7; lane 8, patient 10; lane 9, patient 13; and lane 10, patient 14.

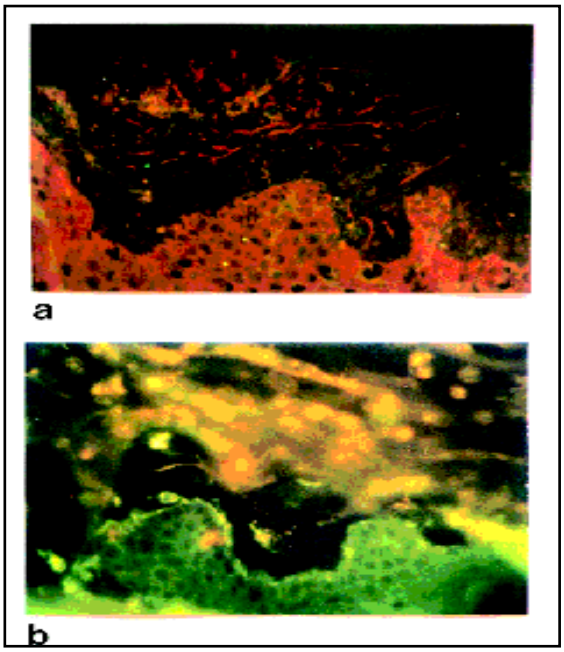

Figure 2 - Immunofluorescence labeling of C-terminal laminin-α2 chain (80 kDa) in skin biopsies from patient 7 (a) and normal control (b).

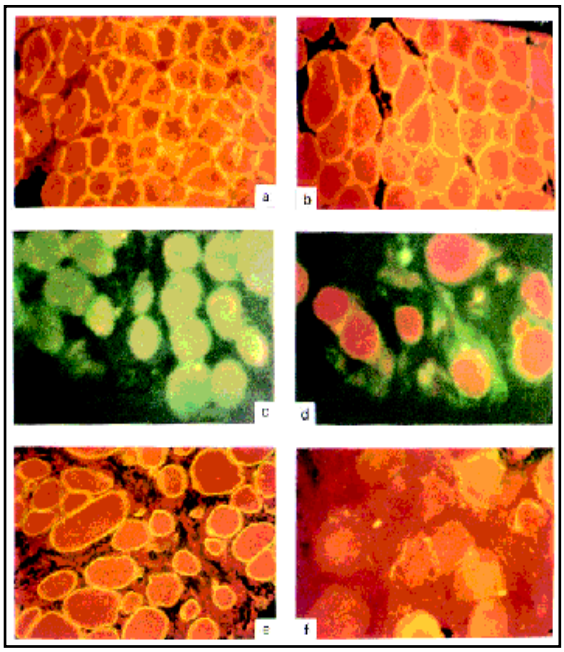

Figure 3 - Immunofluorescence labeling of C-terminal laminin-α2 chain (80 kDa) in skeletal muscle from patient 3 (c), patient 12 (e) and normal control (a). Immunofluorescence labeling of N-terminal laminin-α2 chain (300 kDa) in skeletal muscle from patient 3 (d), patient 12 (f) and normal control (b).

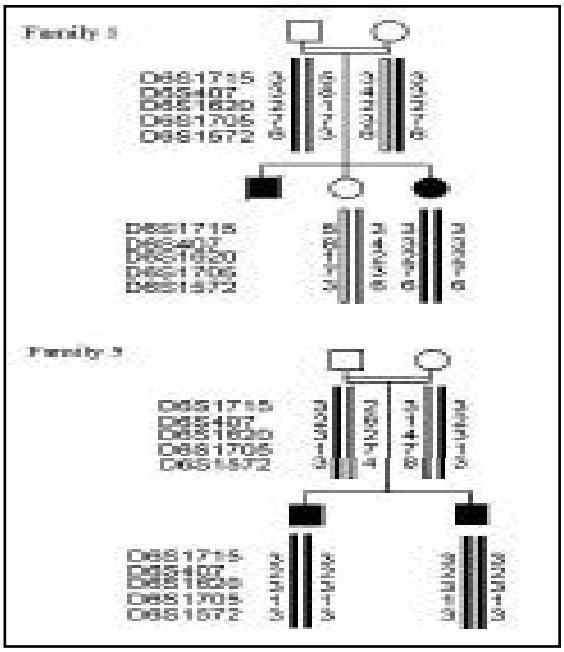

Figure 4 - Haplotypes for 5 polymorphic markers from the genomic region containing the LAMA2 gene. The affected individuals, who are daughters of a first-cousin marriage, are denoted by blackened symbol. A double line indicates the consanguineous mating. The 2 families have been linked to the LAMA2 locus because of homozygosity. Family 1: patient 1; and family 5: patient 6 and 7.

A skin biopsy specimen, obtained from patient 7, showed also an absence of laminin-α2 with the 80 kDa antibody (**Figure 2**). Patient 3, who is the sister of the patient 2, had no immunostaining on her muscle fibres with the anti-80 kDa antibody, while the anti-300 kDa antibody elucidated a weak non-homogeneous signal on most fibres (**Figure 3**). Laminin-α2 immunostaining in patients 8 and 12 showed normal intensity with the 80 kDa antibody, but revealed the absence of fluorescence with anti-300 kDa antibody for the first case and reduced intensity for the second (**Figure 3**). Immunohistochemical study for muscle biopsy of patient 11 showed normal labeling on muscle fibers with both antibodies of laminin-α2. Immunoblot was not performed for this patient. For the 4 patients (2, 4, 5 and 14), investigation of laminin-α2 was performed using only the anti-80 kDa antibody because of the lack of biopsies for these patients (**Table 2, Figure 1**). Immunostaining and immunoblot analyses of muscle fibres of patient 5 showed an absence of laminin-α2 C-terminal region (80 kDa). However, for patients 2 and 4, immunostaining with anti-80 kDa antibody was slightly reduced and relatively uniformly distributed on cell surfaces. Immunoblot showed a specific band for laminin-α2 (**Figure 1**). In patient 14, Laminin-α2 was normally present, when both immunostaining and western blot analyses were performed using the 80 kDa antibody (**Table 2, Figure 1**). Alpha-sarcoglycan, β-dystroglycan and dystrophin immunostaining were normally present on muscle fibre surfaces of patients studied in this series except in patient 3, where dystrophin was partially expressed, α-sarcoglycan was absent and in patient 2 who had a partial immunostaining on muscle fibres with the anti β-dystroglycan antibody (**Table 2**). The immunohistochemical analysis using 2 antibodies for anti-merosin for 10 patients allowed us to conclude for a partial laminin-α2 deficiency in 7 patients, a total deficiency in 2 patients and a normal expression in one patient. However, the use of only anti-80 kDa in the 4 other patients led us to deduce an abnormal expression of C-terminal fragment of laminin-α2 in 3 patients and a normal expression in one case. On the basis of clinical and immunohistochemical data, patients one, 6, 7 and 13 with hypotonia, white matter changes, normal intelligence and laminin-α2 deficiency could be affected by classical CMD form (MDC1A) which is due to LAMA2 gene defects. However, the remaining patients could not be classified when using only clinical and immunohistochemical data.

Genetic analysis. The genetic study was performed on 10 patients belonging to 8 Tunisian families in order to determine whether the deficiency of laminin-α2 detected in the studied patients is a primary genetic defect caused by mutations in the LAMA2 gene or whether it is a secondary deficiency due to other gene defects. Linkage analysis by homozygosity mapping for these families was compatible with linkage to the LAMA2 locus on 6q22 for only 2 families: family one (patient one); family 5 (patients 6 and 7) (**Figure 4**). For the families 2, 6, 7, 8, 10 and 11 (families of patients 2, 3, 8, 9, 10, 12 and 13) genetic analysis excluded any linkage to the explored locus. For families 3, 4, 9 and 12, genetic analysis was not performed. The genetic results confirmed classification of patients one, 6 and 7 in the MDC1A form but excluded patient 13 from this group. The genetic study revealed also that deficiency of laminin-α2 expression in patients 2, 3, 8, 9, 10, and 12 is secondary and could be due to abnormalities in other genes. Four patients (4, 5, 11 and 14) with severe phenotype and with laminin-α2 deficiency could not be classified into the 2 previously mentioned groups due to the lack of genetic exploration. The combination of clinical, immunological and genetic explorations suggest the presence of 3 groups: the first group including 3 classical CMD patients (patients one, 6 and 7) with hypotonia, white matter changes, normal intelligence and primary laminin-α2 deficiency; the second group containing 7 patients (patients 2, 3, 8, 9, 10, 12 and 13) with severe phenotype, mental retardation, central nervous system abnormalities and secondary laminin-α2 deficiency and the last one containing patients 4, 5, 11 and 14 who could not be classified due to the lack of genetic study.

Discussion. Phenotype heterogeneity characterizing CMD constitutes a difficulty in establishing a differential diagnosis. In order to minimize the uncertainty in clinical diagnosis and to improve the classification of 14 Tunisian patients affected with CMD and belonging to 12 families, we used immunohistochemical analysis and genetic study. The majority of published CMD cases have been defined immunocytochemically and only 21% have been studied with more than one laminin-α2 antibody[21] and much less have been studied with other antibodies. In this paper, the immunohistochemical analysis was performed with antibodies against the 2 fragments of laminin-α2 and other sarcolemmal proteins: α-sarcoglycan, β-dystroglycan and dystrophin. The immunohistochemical analysis using 2 anti-merosin antibodies for 10 patients allowed confirmation of partial laminin-α2 deficiency in 7 patients and a total deficiency in 3 patients. Immunoblot analysis using the same anti-80 kDa antibody confirmed the immunohistochemical results. These features illustrated the need to assess laminin-α2 status with more than one antibody; so a wider panel of

antibodies against different regions of this protein is required to avoid false positive or negative results. In fact, among these cases, a normal expression of the 80 kDa fragment was observed with patient 9 who showed a reduced expression of the 300 kDa fragment when tested with the relevant antibody. Recently, the immunohistochemical patterns of 3 CMD cases using several anti-laminin-α2 antibodies have allowed authors to refine the epitopes of the commercially available antibodies and illustrate the importance of antibodies directed against different domains of the protein.[28] The use of more than one antibody was also described in immunohistochemical investigation of Duchenne muscular biopsies, where antibodies recognizing different regions of dystrophin were essential to assess Duchenne dystrophy.[29]

The use of a panel of antibodies covering the laminin-α2 will be required to supervise the search for mutations. In fact, the LAMA2 gene is very large, with 64 exons and a transcript of more than 10 kb,[6,30] and hence, the potential of mutations in different parts of the gene is large.

Expression of laminin-α2 had also been reported in normal skin in the basement membrane at the junction of the dermis and epidermis.[31] We studied a skin biopsy specimen from patient 7, brother of patient 6. Unlike his brother, he showed a partial deficiency of laminin-α2 in his muscle biopsy. However, in his skin biopsy, there was no expression of laminin-α2 at the dermal epidermal junction. Our result was in agreement with previous findings[32] and suggests that the skin biopsy specimen can provide a useful complementary alternative to muscle biopsy samples for a best assessment of laminin-α2.

In addition to the immunohistochemical study, the CMD diagnosis yield may be increased by genetic analysis and allowed to improve classification of patients affected with CMD, especially in cases with secondary laminin-α2 deficiency, which is not due to abnormality in LAMA2 gene. In our study, genetic analyses in families one and 3 (patients one, 6 and 7) were compatible with linkage to the LAMA2 gene on chromosome 6q22, suggesting that the abnormalities in protein expression for patients one, 6 and 7 could be caused by mutation(s) in the LAMA2 gene. In 6 families (2, 6, 7, 8, 10 and 11) of patients with partial reduction in laminin-α2, linkage analysis excluded the LAMA2 gene. These findings suggest that this deficiency is secondary and might be due to defects in other genes. These families were also excluded from other CMD explored loci: MEB, CMD1B, FCMD and RSMD1 loci.[33] Current analyses showed linkage to the MDC1C locus on 19q13.3 for these families (data not shown).

The results of investigation of laminin-α2 expression in Tunisian patients affected with CMD illustrates and confirms the expanding clinical phenotype of patients with laminin-α2 deficiency as described previously.[3] Other recent reports support this variability.[14,34] In fact, we have identified 10 patients with either partial or total laminin-α2 deficiency; but only 4 patients (one, 6, 7 and 13) have the features of the typical classical CMD such as hypotonia, white matter changes and normal intellect. Among these 4 patients, 3 of them belonging to 2 families (one and 5) are linked to the LAMA2 locus. However, patient 13 (family 11) had typical classical CMD features, total laminin-α2 deficiency and showed exclusion from LAMA2 locus. This exclusion is probably due to a recombination phenomenon, which leads to a loss of the homozygosity at 6q22. Only the search for mutations in the LAMA2 gene for this patient could confirm these findings. Patients 2, 3, 8, 9, 10 and 12 with a secondary partial laminin-α2 deficiency had the most severe phenotype characterized by hypotonia, weakness at birth and inability to achieve the upright position with cerebral abnormalities.

In the present study, all patients expressed normal α-sarcoglycan, β-dystroglycan and dystrophin except the 2 patients of family 2 (patients 2 and 3). These patients showed a reduction of expression of α-sarcoglycan and β-dystroglycan. Genetic analysis confirmed the secondary laminin-α2 deficiency in this family and showed that it is linked to MDC1C locus (data not shown).

In summary, we report clinical, immunohistochemical and genetic studies in 14 cases of CMD with variable phenotypes. The combination of the clinical, immunochemical and genetic findings allowed us to divide these patients into 3 groups: a first group with total laminin-α2 deficiency, classical CMD features and linked to LAMA2 gene, a second group with a severe phenotype, partial laminin-α2 deficiency and excluded from the LAMA2 locus and the third one which could not be exactly classified due to the lack of genetic study.

Acknowledgment. We thank the patients and their families for their participation. We wish to thank Mrs Leila Hakim for helping us to perform immunostaining. We thank Ministère de la Recherche Scientifique et de la Technologie and l'Association Française contre les Myopathies AFM (France) for financial support. We also thank Mr Jamil Jaoua for proofreading this paper.

References

1. Dubowitz V. Workshop report 22nd ENMC sponsored workshop on congenital muscular dystrophy, Baarn, Netherlands, May 1993. ***Neuromuscul Disord*** 1994; 4: 75-81.

2. Dubowitz V. Muscle disorders in childhood. 2nd ed. London (UK): WB Saunders; 1995. p. 93-105.
3. Tome FM, Evangelista T, Leclerc A, Sunada Y, Manole E, Estournet B et al. Congenital muscular dystrophy with merosin deficiency. ***C R Acad Sci III*** 1994; 317: 351-357.
4. Sewry CA, Philpot J, Mahony D, Wilson LA, Muntoni F, Dubowitz V. Expression of laminin subunits in congenital muscular dystrophy. ***Neuromuscul Disord*** 1995; 5: 307-316.
5. Hillaire D, Leclerc A, Faure S, Topaloglu H, Chiannilkulchai N, Guicheney P et al. Localisation of merosin-negative congenital muscular dystrophy to chromosome 6q2 by homozygosity mapping. ***Hum Mol Genet*** 1994; 3: 1657-1661.
6. Helbling-Leclerc A, Topaloglu H, Tome FM, Sewry C, Gyapay G, Naom I et al. Readjusting the localization of merosin (laminin alpha2-chain) deficient congenital muscular dystrophy locus on chromosome 6q2. ***C R Acad Sci III*** 1995; 318: 1245-1252.
7. Fukuyama Y, Osawa M, Suzuki H. Congenital progressive muscular dystrophy of the Fukuyama type: clinical, genetic and pathological considerations. ***Brain Dev*** 1981; 3: 1-29.
8. Dobyns WB, Pagon RA, Armstrong D, Curry CJ, Greenberg F, Grix A et al. Diagnosis criteria for Walker-Warburg syndrome. ***Am J Med Genet*** 1989; 32: 195-210.
9. Santavaouri P, Somer H, Sainio K. Muscle-eye-brain disease (MEB). ***Brain Dev*** 1989; 11: 147-153.
10. Kobayashi K, Nakahori Y, Miyake M, Matsumura K, Kondo-Iida E, Nomura Y et al. An ancient retrotransposal insertion causes Fukuyama-type congenital muscular dystrophy. ***Nature*** 1998; 394: 388-392.
11. Beltran-Valero De Bernabe D, Currier S, Steinbrecher A, Celli J, Van Beusekom E, Van Der Zwaag B et al. Mutations in the O-Mannosyltransferase Gene POMT1 Give Rise to the Severe Neuronal Migration Disorder Walker-Warburg Syndrome. ***Am J Hum Genet*** 2002; 71: 1033-1043.
12. Yoshida A, Kobayashi K, Manya H, Taniguchi K, Kano H, Mizuno M et al. Muscular Dystrophy and Neuronal Migration Disorder Caused by Mutations in a Glycosyltransferase, POMGnT1. ***Dev Cell*** 2001; 1: 717-724.
13. Brockington M, Sewry CA, Herrmann R, Naom I, Dearlove A, Rhodes M et al. Assignment of a form of congenital muscular dystrophy with secondary merosin deficiency to chromosome 1q42. ***Am J Hum Genet*** 2000; 66: 428-435.
14. Brockington M, Blake DJ, Prandini P, Brown SC, Torelli S, Benson MA et al. Mutations in the fukutin-related protein gene (FKRP) cause a form of congenital muscular dystrophy with secondary laminin alpha2 deficiency and abnormal glycosylation of alpha-dystroglycan. ***Am J Hum Genet*** 2001; 69: 1198-1209.
15. Voit T, Sewry CA, Meyer K, Hermann R, Straub V, Muntoni F et al. Preserved merosin M chain (or laminin alpha2) expression in skeletal muscle membrane distinguishes Walker-warburg syndrome from Fukuyama muscular dystrophy and merosin-deficient congenital muscular dystrophy. ***Neuropediatrics*** 1995; 26: 148-155.
16. Haltia M, Leivo I, Somer H, Pihko H, Paetau A, Kivela T et al. Muscle-eye-brain disease: a neuropathological study. ***Ann Neurol*** 1997; 4: 173-180.
17. Matsumura K, Nonaka I, Campbell KP. Abnormal expression of dystrophin-associated proteins in Fukuyama-type congenital muscular dystrophy. ***Lancet*** 1993; 341: 521-522.
18. Matsumura K, Tome FM, Collin H, Azibi K, Chaouch M, Kaplan JC et al. Deficiency of the 50 k dystrophin-associated-glycoprotein in sarcolemma of severe childhood autosomal recessive muscular dystrophy. ***Nature*** 1992; 359: 320-322.
19. Hayashi YK, Ogawa M, Tagawa K, Noguchi S, Ishihara T, Nonaka I et al. Selective deficiency of alpha-dystroglycan in Fukuyama-type congenital muscular dystrophy. ***Neurology*** 2001; 57: 115-121.
20. Hayashi YK, Engvall E, Arikawa-Hirasawa E, Goto K, Koga R, Nonaka I et al. Abnormal localization of laminin subunits in muscular dystrophies. ***J Neurol Sci*** 1993; 119: 53-64.
21. Jones KJ, Morgan G, Johnston H, Tobias V, Ouvrier RA, Wilkinson I et al. The expanding phenotype of laminin α2 chain (merosin) abnormalities: case series and review. ***J Med Genet*** 2001; 38: 649-657.
22. Kobayashi O, Hayashi Y, Arahata K, Ozawa E, Nonaka I. Congenital muscular dystrophy: clinical and pathological study of 50 patients with the classical (Occidental) merosin-positive form. ***Neurology*** 1996; 46: 815-818.
23. Jones KJ, Kim SS, North KN. Abnormalities of dystrophin, the sarcoglycans, and laminin alpha2 in the muscular dystrophies. ***J Med Genet*** 1998; 35: 379-386.
24. Herrmann R, Straub V, Meyer K, Kahn T, Wagner M, Voit T. Congenital muscular dystrophy with laminin alpha2 chain deficiency: identification of new intermediate phenotype and correlation of clinical findings to muscle immunohistochemistry. ***Eur J Pediatr*** 1996; 155: 968-976.
25. Morandi L, Di Blasi C, Farina L, Sorokin L, Uziel G, Azan G et al. Clinical correlations in 16 patients with total or partial laminin alpha2 deficiency characterized using antibodies against 2 fragments of the protein. ***Arch Neurol*** 1999; 56: 209-215.
26. Nicholson LV, Davison K, Falcous G, Hardwood C, O'Donnell E, Slater CR et al. Dystrophin in skeletal muscle. I. Western blot analysis using a monoclonal antibody. ***J Neurol Sci*** 1989; 94: 125-136.
27. Kawazaki E. Sample preparation from blood, cells and other fluids. In: Innis M, Gelffand D, Snisky G, White T, editors. PCR protocols. A guide to methods and application. San Diago (CA): Academic Press; 1990.p. 146-152.
28. He Y, Jones KJ, Vignier N, Morgan G, Chevallay M, Barois A et al. Congenital muscular dystrophy with primary partial laminin alpha2 chain deficiency: molecular study. ***Neurology*** 2001; 57: 1319-1322.
29. Bulman DE, Murphy EG, Zubrzycka-Gaarn EE, Worton RG, Ray PN. Differentiation of Duchenne and Becker muscular dystrophy phenotype with amino and carboxy-terminal antisera specific for dystrophin. ***Am J Hum Genet*** 1991; 48: 295-304.
30. Guicheney P, Vignier N, Helbling-Leclerc A, Nissinen M, Zhang X, Cruaud C et al. Genetics of laminin α2 chain (or merosin) deficient congenital muscular dystrophy: from identification of mutations to prenatal diagnosis. ***Neuromuscul Disord*** 1997; 7: 180-186.
31. Sewry CA, D'Alessandro M, Wilson LA, Sorokin LM, Naom I, Bruno S et al. Expression of laminin chains in skin in merosin-deficient congenital muscular dystrophy. ***Neuropediatrics*** 1997; 28: 217-222.
32. Sewry CA, Philpot J, Sorokin LM, Wilson LA, Naom I, Goodwin F et al. Diagnosis of merosin (laminin-2) deficient congenital muscular dystrophy by skin biopsy. ***Lancet*** 1996; 347: 582-584.
33. Triki C, Louhichi N, Méziou M, Choyakh F, Kéchaou MS, Jlidi R et al. Merosin-deficient congenital muscular dystrophy with mental retardation and cerebellar cysts in three Tunisian patients unlinked to the LAMA2, FCMD, MEB and CMD1B. ***Neuromuscul Disord*** 2003; 13: 4-12.
34. Brockington M, Yuva Y, Prandini P, Brown SC, Torelli S, Benson MA et al. Mutations in the Fukutin Related-Protein gene (FKRP) identifies Limb Girdle Muscular Dystrophy 2I as a milder allelic variant of congenital muscular dystrophy MDC1C. ***Hum Mol Gen*** 2001; 10: 2851-2859.